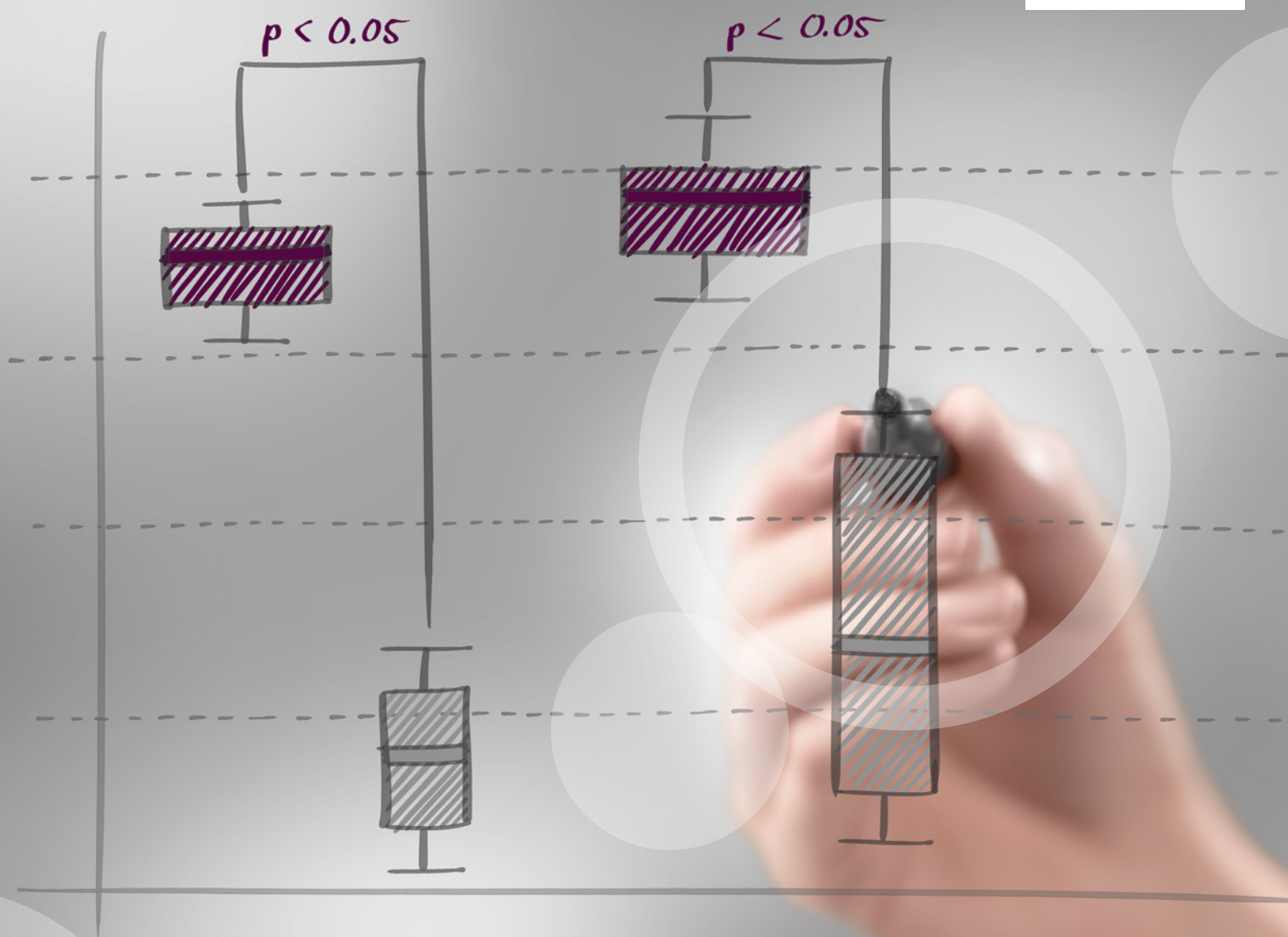

Premium® Tooth

Aesthetic complications. A treatment protocol for fixed prostheses.

- Dr Fernanda Werneck

Giving a hand to oral health.



KULZER
MITSUI CHEMICALS GROUP

Treatment of aesthetic complications in protocol prostheses

Clinical case report

A patient with an upper implant supported prosthesis, presented with functional and mainly aesthetic difficulties related to exposure, when smiling, of the junction between the upper edge of the fixed prosthesis and the gingival margin. There was also difficulty in cleaning for long-term hygiene. For the ideal treatment and restoration treatment plan, the use of CT-scan images, complete photographic protocol and aesthetic-functional intraoral analysis were essential. This process being a fundamental pillar for the correct direction and a mutual understanding of all involved. Through identification, based on the patient's characteristics, we carried out our treatment plan. The purpose of this report is to show workflow through the brief presentation of one (1) clinical case for retreating atrophic maxillae by initially using bilateral bone graft in the maxillary sinuses, removing poorly positioned implants and then performing prosthetic restoration: restoring the aesthetics and function associated with facial harmony.

Materials used

Premium® Tooth

Author

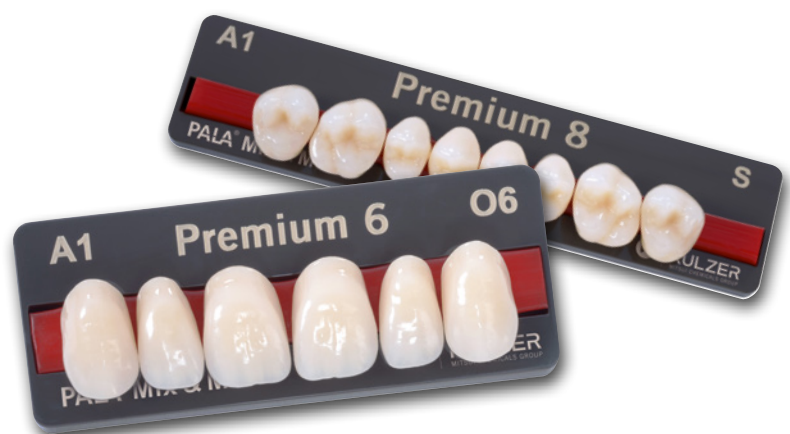

Dr Fernanda Werneck

Dental Prosthesis Specialist

Tutor of Introductory Course on Treatment of Atrophic Maxillae, IPENO – Florianópolis.

Email: fe.werneck@hotmail.com



Case images

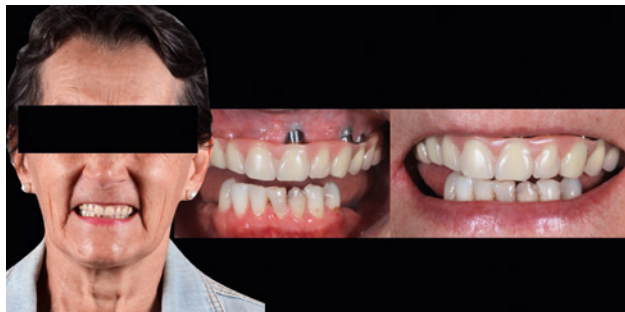

Figure 01 – Appearance and initial planning by means of systemic assessment of the patient and extra and intraoral analysis.

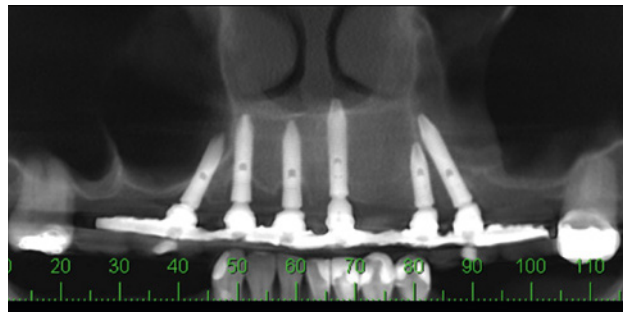


Figure 02 – Initial CT-scan examination.

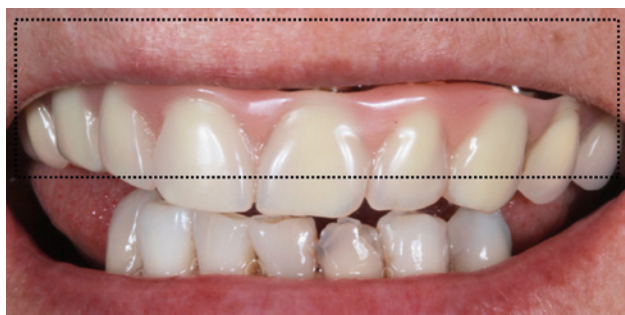

Figure 03 – Assessment of compromised transition zone.

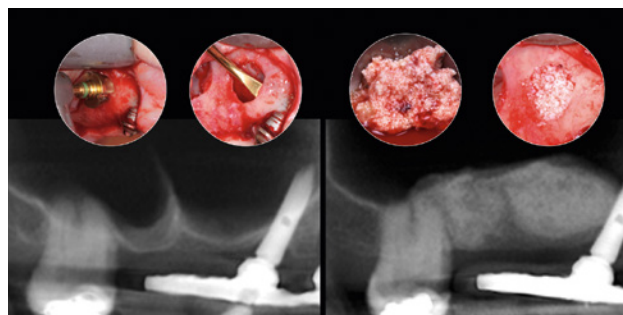


Figure 04 – Bone graft by bilateral maxillary sinus lifting.

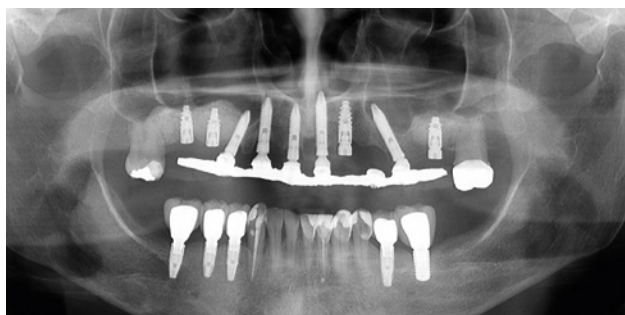


Figure 05 – At six months, installation of implants in the grafting area.



Figure 06 – Choice of teeth through facial analysis and intraoral appearance.

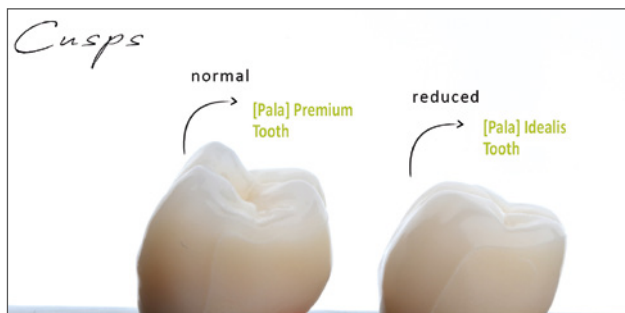

Figure 07 – Selection of posterior teeth.

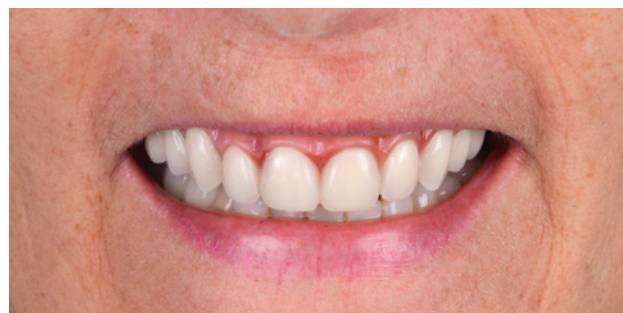

Figure 08 – Aesthetic and functional test.

Case images

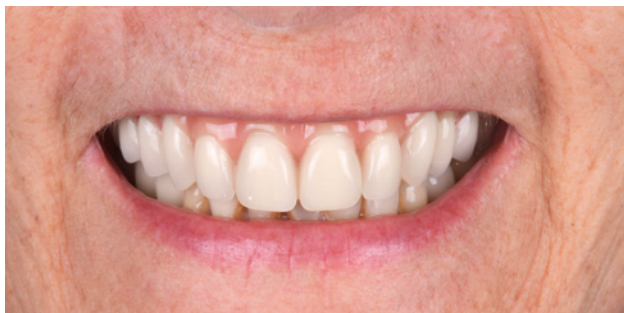

Figure 09 – Try-in of the provisional prosthesis.



Figure 10 – Surgical phase 2 – Removal of poorly positioned implants.

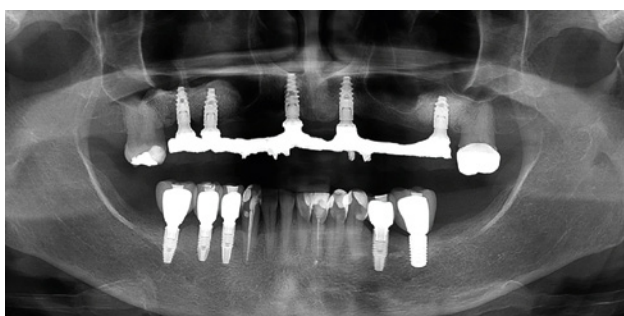

Figure 11 – Regularisation of bone border and installation of new implants.

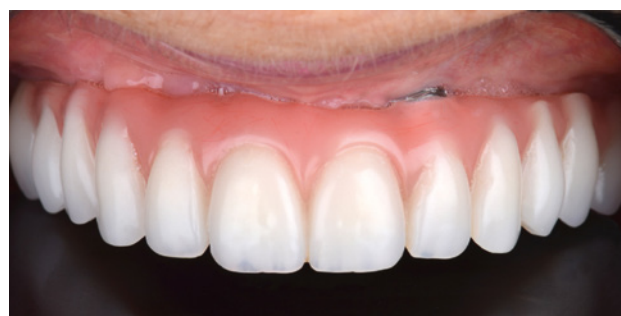

Figure 12 – The provisional prosthesis in situ.

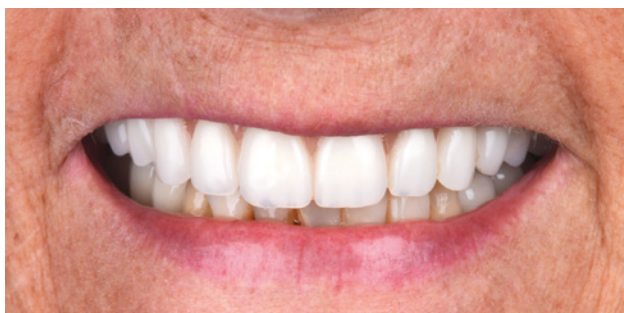

Figure 13 – Final smile.




Figure 14 – Correct positioning of upper teeth (vertical and horizontal).

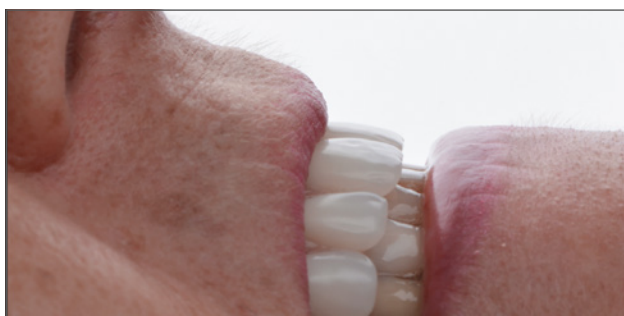

Figure 15 – Lip support.

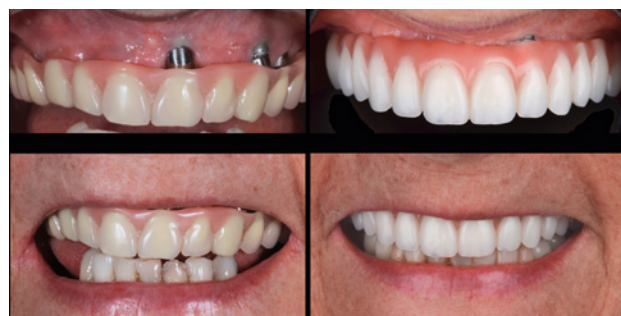

Figure 16 – Initial and final appearance.