



PreVISION®

Tips & Tricks

Tips & Tricks

Direct fabrication of provisionals.

Giving a hand to oral health.



KULZER
MITSUI CHEMICALS GROUP

Content

01	Manufacturing techniques	p. 06	06	Preparation of provisional crown and bridge material	p. 13
02	Impression materials	p. 07	07	Loading the impression	p. 14
03	Preliminary impression	p. 08	08	Removal	p. 16
04	Trimming of the impression	p. 10	09	Intraoral cleaning	p. 18
05	Repositioning of the impression	p. 12	10	First steps after completion of setting	p. 19

11

Excess removal

p. 20

12

Trimming

p. 22

13

Design

p. 24

14

Finishing procedures

p. 26

15

Final try-in

p. 28

16

Temporary cementation

p. 29

17

Excess removal

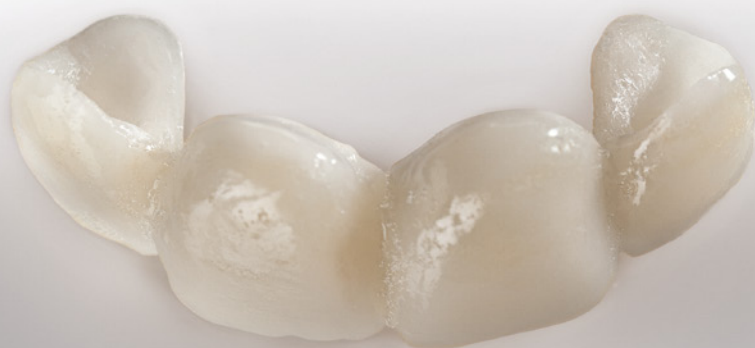p. 30

FAQs

p. 32

Notes

p. 34



Introduction

The fabrication of a provisional is an integral part of the fabrication process of fixed dental restorations. As a temporary solution the provisional fulfills numerous tasks: It protects the tooth-structure against thermal, chemical, mechanical and microbial stimuli. It preserves the occlusion and the masticatory function as well as restores esthetics and phonetics. Tooth movements like tilting or elongation are prevented and the marginal periodontal tissue is protected. Furthermore provisionals can also serve for diagnostic purposes when having abutment teeth with a doubtful prognosis or for prospective diagnostics (planned modifications of occlusion, phonetics or esthetics).

Aim of Kulzer is not only to supply dentists and dental technicians with reliable materials, but also to be a competent partner for dental questions. This tips and tricks guide for the direct fabrication of provisionals is based on the extensive experience and cooperation with dental professionals and comprises practical advice on the easy and quick fabrication of a temporary restoration.



Dr. med. dent. Andrea Leyer
Global Scientific Affairs Manager Disease Management and
Pain Control, Indirect Restorations
Hanau (Germany), February 2015



01

Manufacturing techniques

Basically, there are three different methods for the fabrication of provisionals: the indirect method, the direct method, as well as a combination of these two.

In the indirect method like the deep-drawing process the provisional is completely fabricated in the dental lab on the basis of a gypsum model. As the indirect procedure is more costly and time-consuming than the direct procedure, it is rather used for larger restorations or long-term provisionals (3 months or longer).

In the direct technique the provisional is directly produced in the patient's mouth, usually under use of an anatomic impression taken prior to the preparation, the so called preliminary impression (fig. 1).

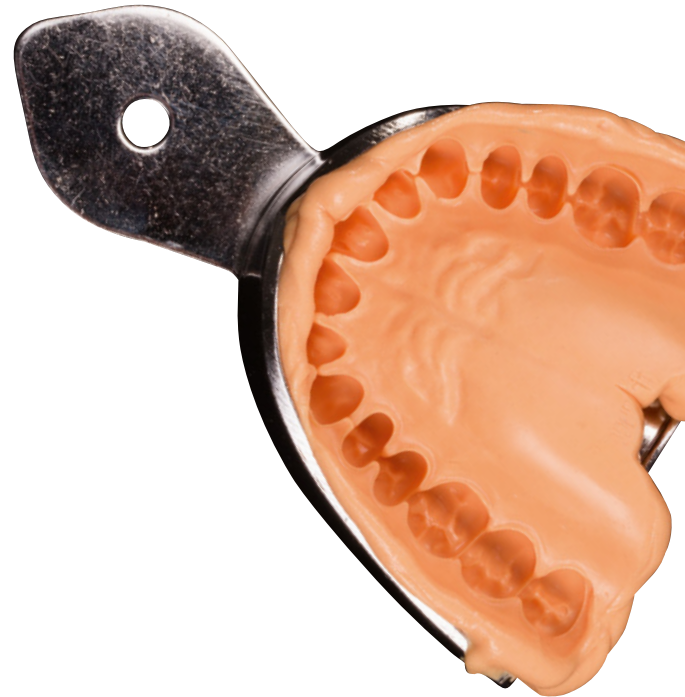

Fig. 1: Preliminary impression: Anatomic impression taken prior to the preparation.

Impression materials

Usually alginates or alginate substitutes are used for the preliminary impression.

Alginates are sufficiently accurate and less costly. Disadvantage of their utilization is that they have poor long-term storage stability. A repair or redoing of the provisional at a later stage is not possible with the alginate impression.

Alginate substitutes (fig. 2) are addition-curing silicones which can be used for all typical alginate applications but offer improved handling and higher dimensional stability than traditional alginates. Alginate substitutes allow an easy, fast, economical and hygienic processing. Advantage of their usage also is the long-term storage stability. A damaged or lost provisional can be quickly repaired or redone with the alginate substitute impression at a later stage.

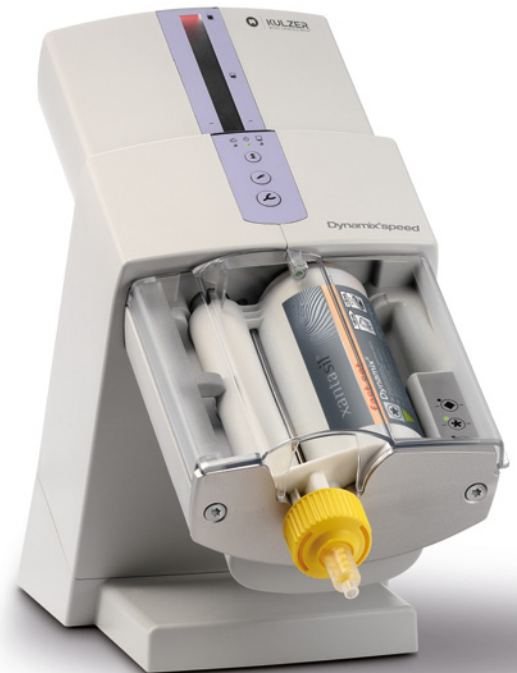

Fig. 2: Alginate substitute xantasil: a medium flow A-silicone, well suited for the preliminary impression for the fabrication of temporary restorations.

03

Preliminary impression

First step is the anatomic impression prior to the preparation (fig. 3):

- Cleaning of the teeth.
- Select an appropriate impression tray, i.e. sufficient space for the impression material between the tray wall and the jaw is necessary: minimum 3 mm for elastomers, 4 mm for alginates. A tray that is too small may be difficult to remove, resulting in plastic deformation of the impression.
- Block out extensive undercuts, e.g. from suspended bridge elements or fixed retainers, with wax or a suitable 'block out' material prior to impression taking. Don't forget to remove the material from the mouth afterwards.



Tip: For smaller restorations a partial impression with a partial impression tray may be sufficient (fig. 4). Thus material can be saved and the process is more convenient for the patient.

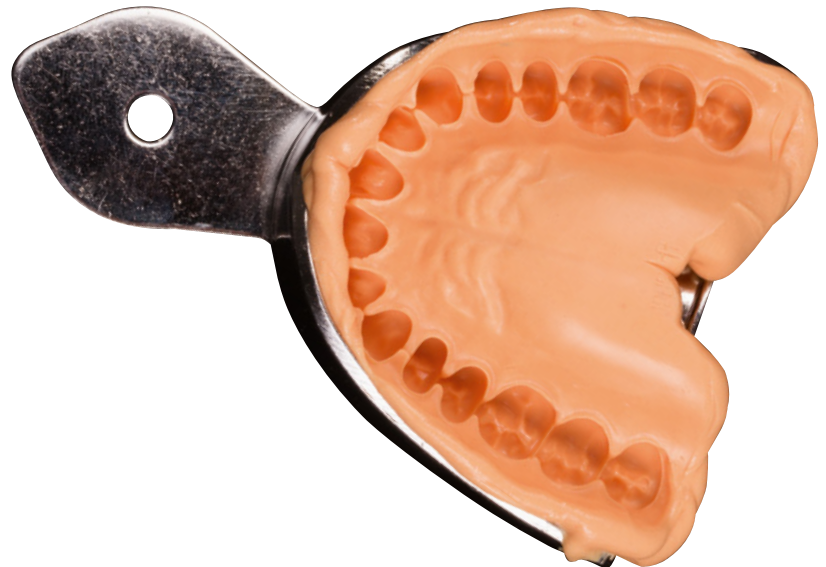

Fig. 3: Preliminary impression with xantasil.



Tip: Impressions made from alginate substitutes like e.g. xantasil can be stored for the entire treatment period.

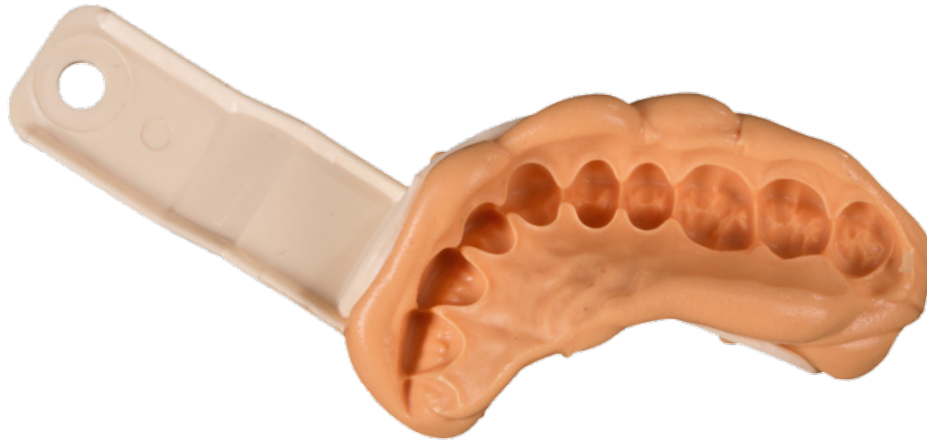


Fig. 4: Partial impression with xantasil.



Hint: Using plastic impression trays, it should be ensured that they are sufficiently rigid respectively torsion resistant.

04

Trimming of the impression

- Cut away material that is exceeding the rim of the impression tray (fig. 5).
- Cut away interdental areas for an easy intraoral repositioning of the impression respectively for a reinforcement of the temporary (fig. 5&6).
- Slightly cut back the cervical area in the region of the prepared teeth to allow a tension-free seating of the provisional ("tray effect") and to have enough material for trimming and finishing the margins of the provisional later (fig. 6).
- For temporary bridges in the molar region where no existing bridge restoration is present: carve out the area of the missing tooth in the preliminary impression as a block to create space for the bridge unit.



Tip: A locating groove in the impression material between the two central incisors facilitates a quick intraoral positioning of the impression in the correct place (fig. 5).

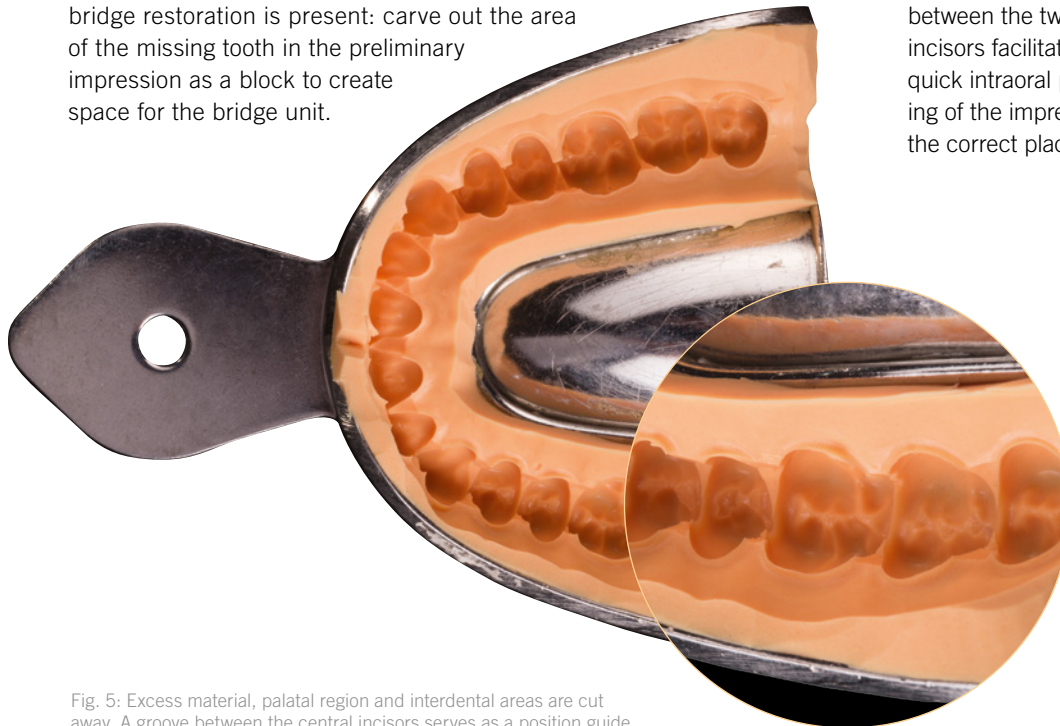


Fig. 5: Excess material, palatal region and interdental areas are cut away. A groove between the central incisors serves as a position guide.

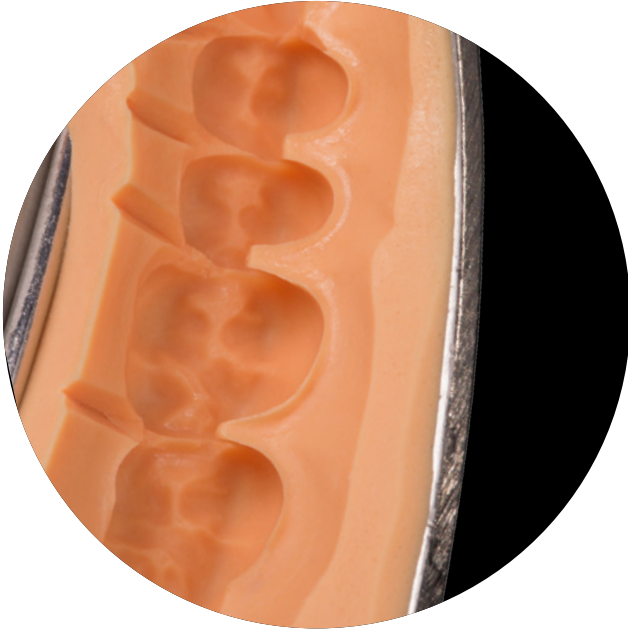

Fig. 6: On the oral side of the prepared area: Slightly cut-back cervical areas, removed interdental areas and 'escape channels'. Interdental areas on the vestibular side are left behind as form-generating elements.



Tip: Leaving the vestibular interdental areas in place, the natural shaping of the teeth can be used as form-generating element to save time in the trimming process (fig. 6).



Fig. 7: Special impression cutting tool U-Cutter to carve the 'escape channels'.



Tip: In the area of the prepared teeth only cut away the interdental areas on the oral side and extend them to act as 'escape channels' (fig. 6 & 7). Thus excess provisional material can flow out to avoid a raised bite.

05

Repositioning of the impression

- After trimming the impression reposition the impression and check the accurate fit.
- Clean and dry the impression.
- Check for loose material flags with the air syringe and if present, remove them (fig. 8). Loose material flags or residues can be incorporated into the provisional material or affect the correct seating of the impression.



Hint: If the repositioning procedure leads to a tearing of the impression material in some spots, this indicates that the impression is not sufficiently cut back in that area.



Tip: Loose flags of the impression material can be easily detected with the air syringe.

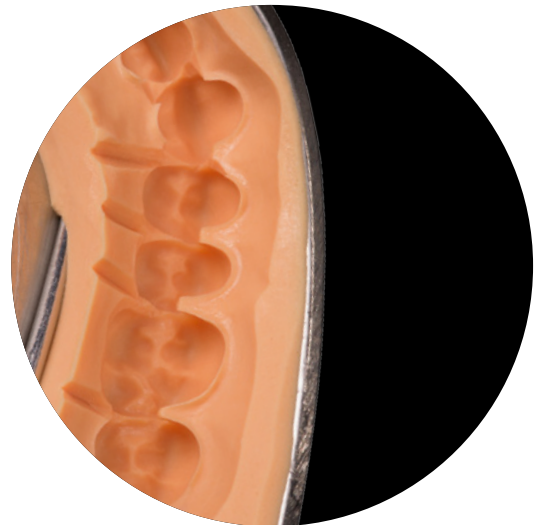

Fig. 8: Ready prepared preliminary impression. When using the air syringe no material flags should be moving in the air stream.

Preparation of provisional crown and bridge material

- Usually composite-based temporary materials (fig. 9) are used for the fabrication of provisionals because they are superior to powder and liquid systems (MMA/PMMA) in handling and mechanical properties.
- Choose the appropriate color of the provisional crown and bridge material.
- Due to technical reasons the filling level of the two chambers of auto-mixing two-component provisional materials can slightly differ. Thus, most manufacturers recommend bleeding of the cartridge prior to the very first use until both pastes are evenly delivered (fig. 11).
- It is recommended to discard the first pea-sized amount of material from each new mixing tip (fig. 10).

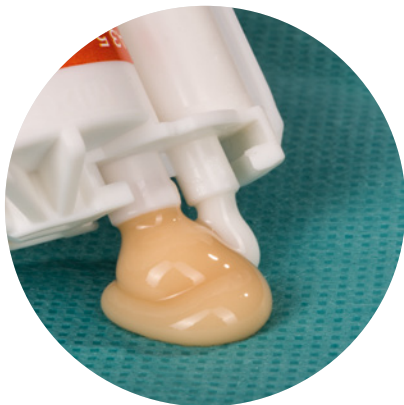

Fig. 11: Bleeding of the cartridge prior to the first use.

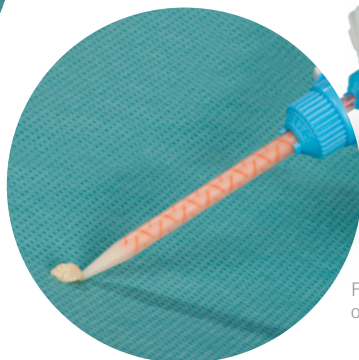

Fig. 10: Discarding the first pea-sized amount of material from each new mixing tip.



Fig. 9: Self-curing two-component material PreVISION Temp in the 10:1 cartridge for the fabrication of provisional temporaries.

07

Loading the impression

- Begin with dispensing the material into the impression at the deepest point of the occlusal surface in the area of preparation (fig. 12).
- Always keep the tip of the mixing tip immersed in the provisional material to avoid the inclusion of air voids (fig. 13).
- Load the impression in the respective area approximately to the level of the marginal gingiva respectively the preparation margin (fig. 14).
- Reposition the impression in the mouth and keep it in place without pressure.

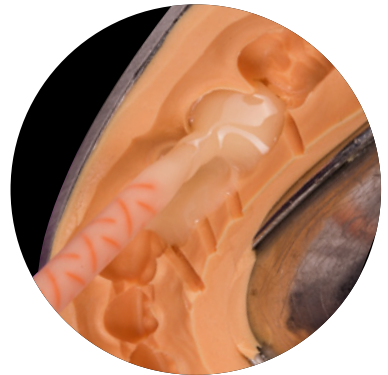
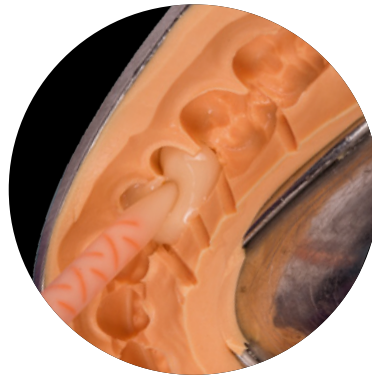
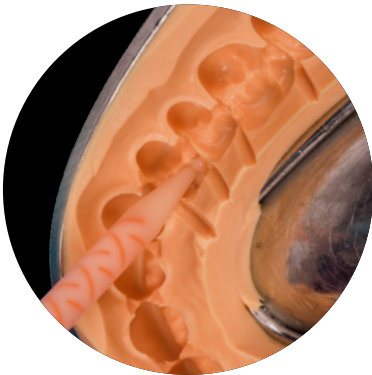Fig. 12: Beginning at the deepest point at the occlusal surface in the impression.

Fig. 13: Always keeping the tip immersed in the material.

Fig. 14: Loading to the gingival margin respectively the preparation margin.



Tip: At the end apply a small amount of material on the treatment tray (fig. 15). The sample will serve as a test piece to determine the moment of impression removal.

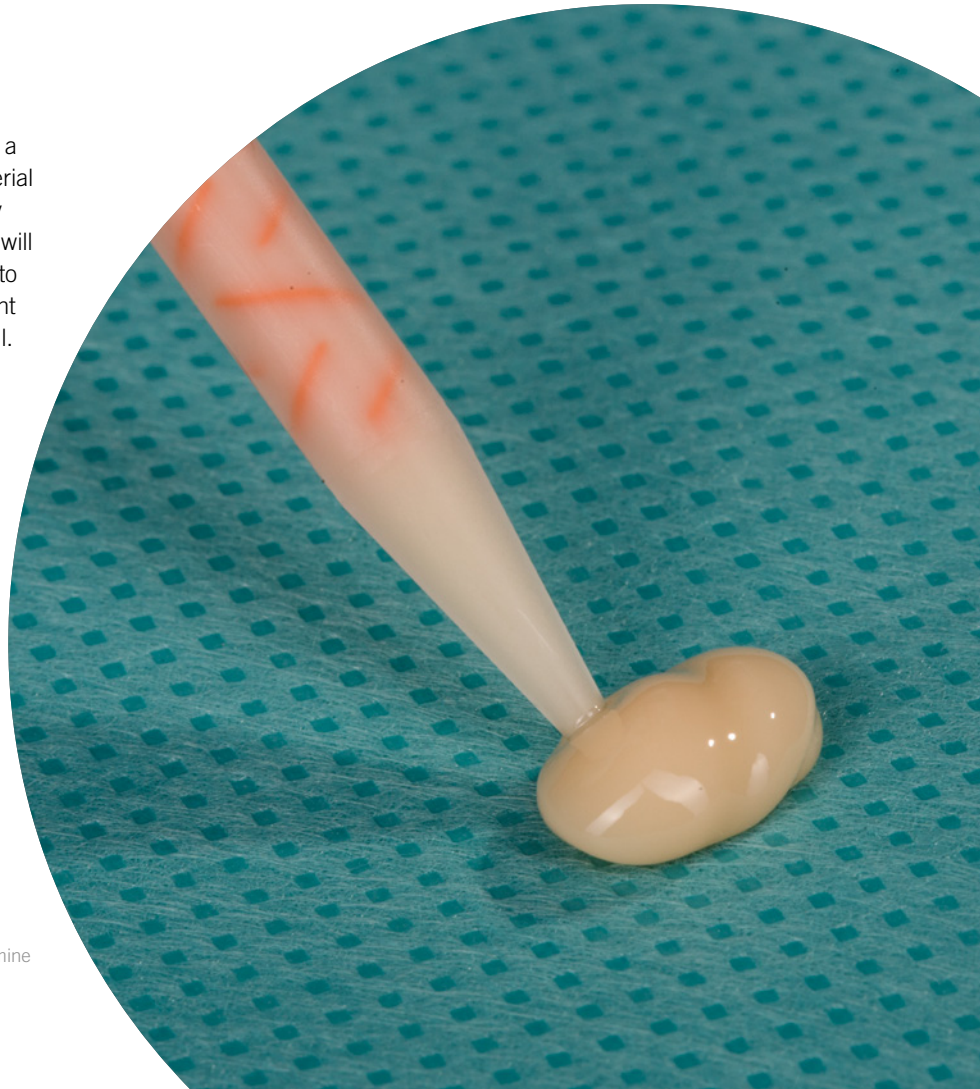


Fig. 15: Application of a material sample to determine the moment of impression removal.

08

Removal

Ideally the provisional is removed before its fully cured – in an elastic state. Only in the elastic state it is possible to easily remove the provisional, especially from undercuts below the preparation margin or interdental areas.



Tip: Determining the point of removal (fig. 16). When the material sample on the treatment tray can be cut easily with the Heidemann spatula without sticking to the spatula or pulling threads, the provisional should be quickly removed from the mouth.

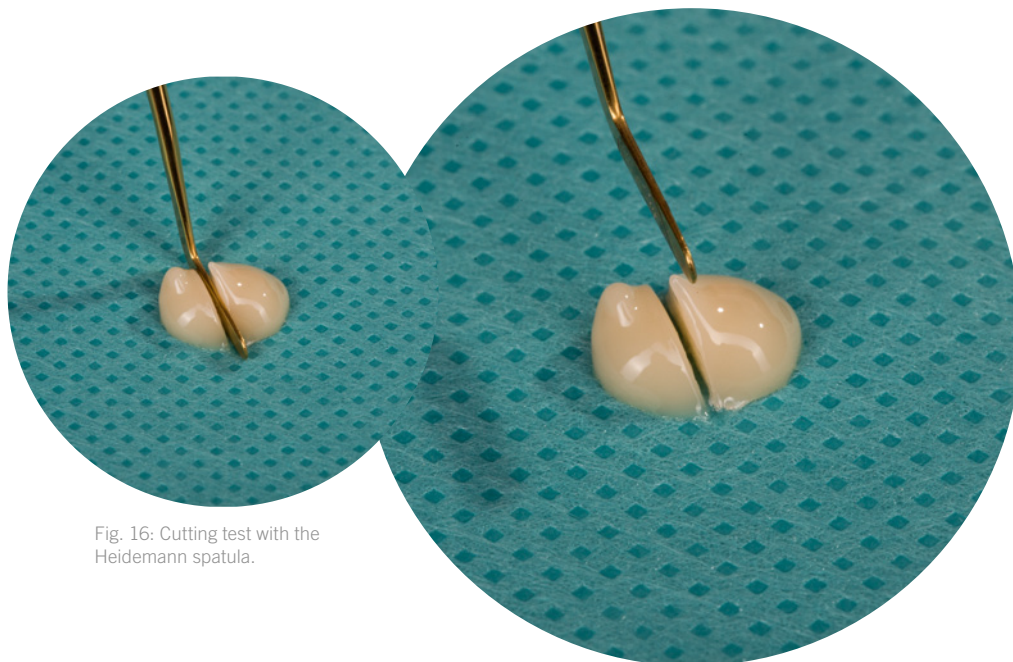
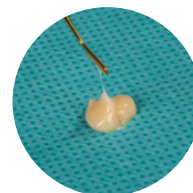


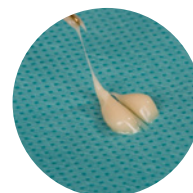Fig. 16: Cutting test with the Heidemann spatula.



Caution!



Far too early for removal, the material is too liquid.



Yet too early, the material still is pulling threads.

As soon as the sample can be cut without pulling threads, the provisional should be removed from the mouth.

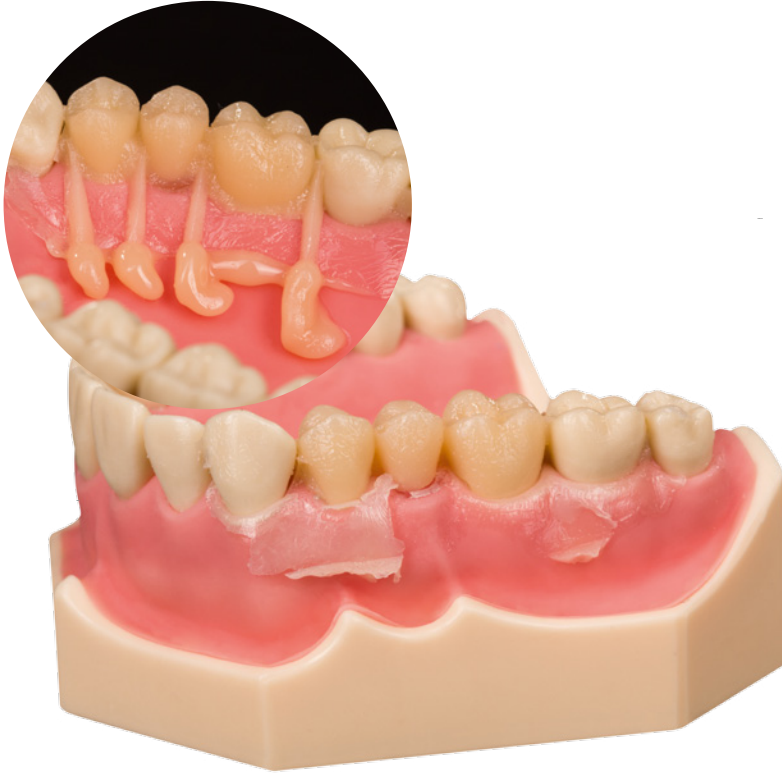

Fig. 17: Provisional remained on the teeth. Excess material could flow off through the 'escape channels' on the palatal side.



Hint: Repeated fracture of the provisional at the same spot might be a hint for too thin prepared areas. Check the preparation and prepare again if necessary or further cut away the impression material in the respective area.

A provisional that remains on the teeth during impression removal (fig. 17) should be quickly removed with the help of a Heidemann spatula. To avoid deformation, the provisional should subsequently be repositioned in the impression (fig. 18) for the completion of setting.

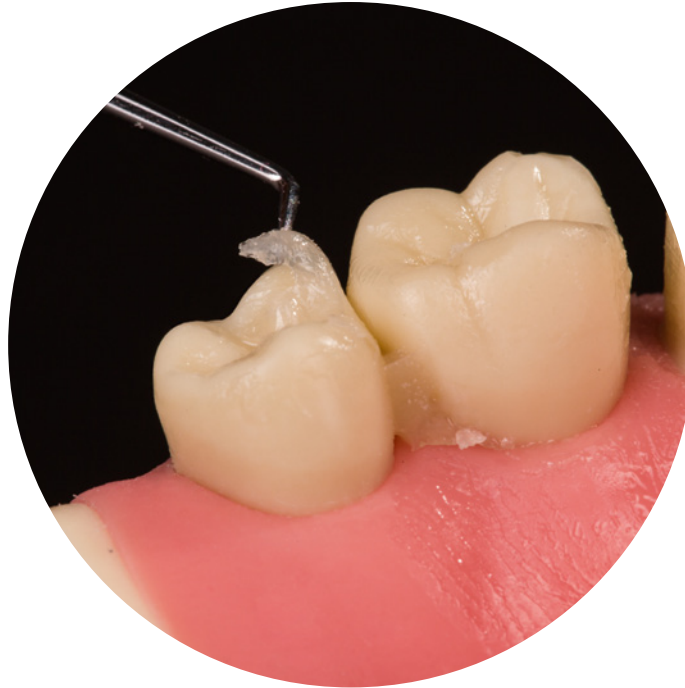

Fig. 18: For completion of setting the provisional is repositioned in the impression.

09

Intraoral cleaning

- The time during the setting process can be used for intraoral cleaning.
- Thorough elimination of all material residues from neighboring teeth, interdental areas and sulcus regions.
- Remaining material (fig. 19) can easily cause an inflammation of the gums: unpleasant for the patient, can result in impeding bleeding during the later seating of the final restoration.



Hint: Shall the precision impression be taken in the same session after the fabrication of the provisional with a methacrylate-based temporary material: the smear layer on the teeth needs to be removed with a cotton pellet and alcohol prior to impression taking. A remaining smear layer might impair the setting of the impression material during the subsequent precision impression.

Fig. 19: Thin, often hardly visible layer of the provisional material on the neighboring teeth.

First steps after completion of setting

- Removal of the provisional from the impression after completion of setting.
- Examine the restoration for completeness.
- To facilitate the trimming process, remove the sticky smear layer with alcohol (fig. 20). A remaining smear layer can hamper high-gloss polishing and the temp can pick up stain easily and have an unpleasant taste in the mouth.

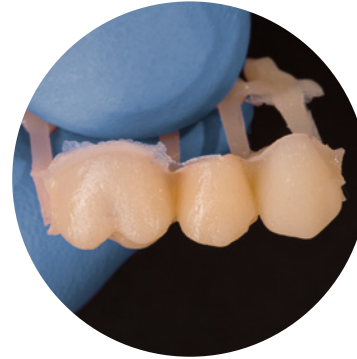

Fig. 20: By comparison, a thin superficial oxygen inhibition layer is visible: at the premolar the inhibition layer is removed but not yet at the molar tooth.



Hint: In case of small imperfections: as long as the oxygen inhibition layer (smear layer) is existing on the temporary, extra material (provisional c&b material or a flowable, lightcuring composite material) can be added.



Tip: To release bridge restorations loosen, them equally from the mesial and distal side with the Heidemann spatula (fig. 21).

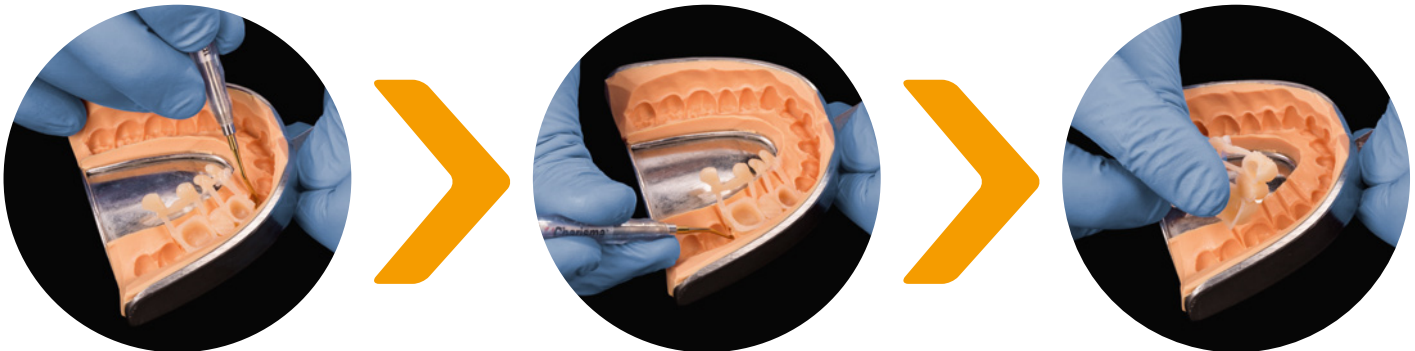

Fig. 21: For an easy release, loosen the bridge restoration from mesial and distal with a Heidemann spatula. Position the spatula between provisional and impression material.

11

Excess removal

- At first remove coarse excess with a scalpel (fig. 22) to minimize the grinding work.
- For excess removal respectively initial trimming with rotating instruments fine crosscut tungsten carbide burs (red ring, HM 79 FX/ISO-size 040) are well suited.
- To protect the patient from being exposed to abrasive dust or a catapulted provisional, the trimming and finishing procedures should be conducted behind the patient.
- If possible use suction.
- Good support is always necessary: support your forearms on the worktop and prop the own fingers against each other (fig. 23).

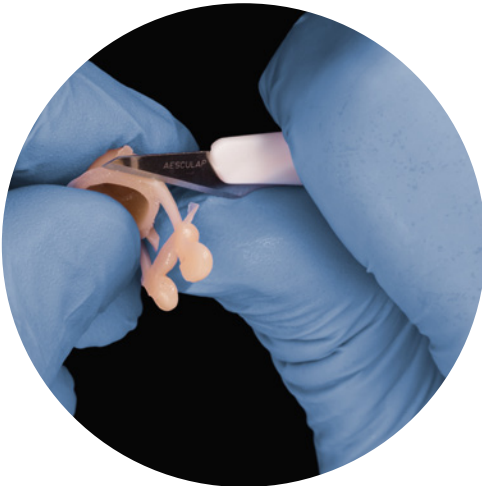

Fig. 22: Excess removal with the scalpel.




Fig. 23: During excess removal guide the tungsten carbide bur parallel along the crown margin.



Tip: The illustrated instruments (fig. 24) from the Kulzer Signum Toolkit are well suited for trimming and finishing provisional restorations.



Fig. 24: Complementary rotating instruments: Conical carbide bur with red ring (HM 79 FX/ISO-size 040), small conical carbide bur with red ring (HM 23 FX/ISO-size 023), synthetic fiber brush (hard), goat hair brush (soft), woolen buffing wheel.

12

Trimming

- After excess removal follows the initial trimming for the intraoral adjustment of the provisional.
- For stability, hold the bridge restoration mesially and distally between the fingers (fig. 25). Long-span bridges can be additionally supported with one finger in the middle.
- Support the working hand with the holding hand (fig. 25).
- At first adjust the crown margins and approximal regions till the provisional optimally fits intraorally.
- Afterwards adjust occlusion and articulation.
- Remove the abrasive dust from the crown lumina with the air syringe prior to the try-in procedure (fig. 26). None removed and compressed grinding dust results in inaccuracy of fit and potential raised bites.

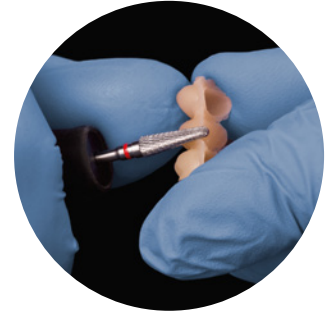


Fig. 25: Hold the bridge restoration mesially and distally between the fingers. The working hand can prop against the holding hand.

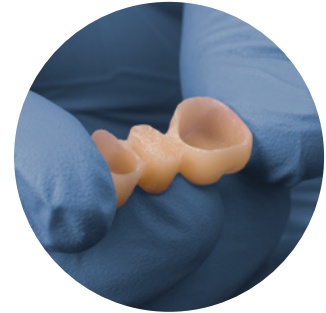



Fig. 26: Remove the grinding dust from the crown lumina prior to the try-in.



Tip: Working at the crown margin: the view should always be directed into the lumen of the crown for a better focus of the preparation margin. The working direction of the bur is always **parallel** to the marginal area (fig. 27) but not directly from above onto the margin (fig. 28).

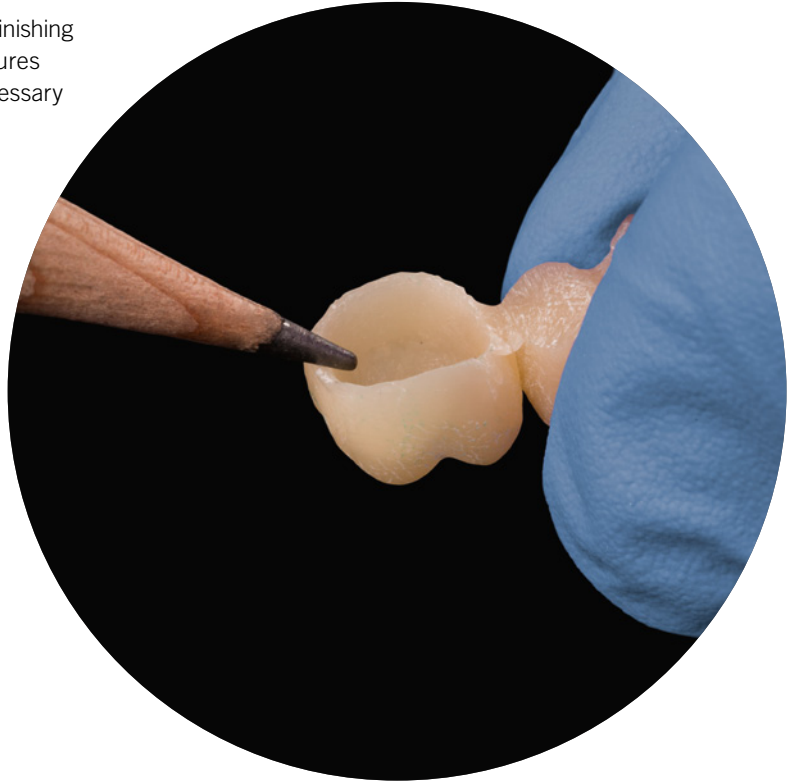
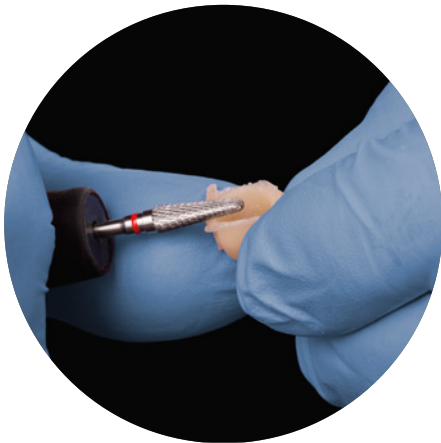Fig. 27: The bur is always directed parallel to the crown margin when working in the marginal area.



Hint: Small voids emerging during trimming and finishing can be easily repaired without additional measures because the oxygen inhibition layer which is necessary for adhesion is still present inside the void.



Caution!



Tip: To avoid damage of the crown margin, the preparation margin can be marked with a pencil on the provisional.

Fig. 28: To avoid too short crown margins, do not work from above onto the margin.

13

Design

- The design of the provisional has to allow the patient to carry out adequate oral hygiene measures.
- Interproximal contacts need to be present and allow flossing.
- The area underneath a bridge pontic needs to be cleanable with interdental brushes.
- To avoid compression of the papilla, create enough space in the interdental regions of multi-unit temporaries.
- A small conical tungsten carbide bur is ideally suited for designing the interdental area (fig. 29).

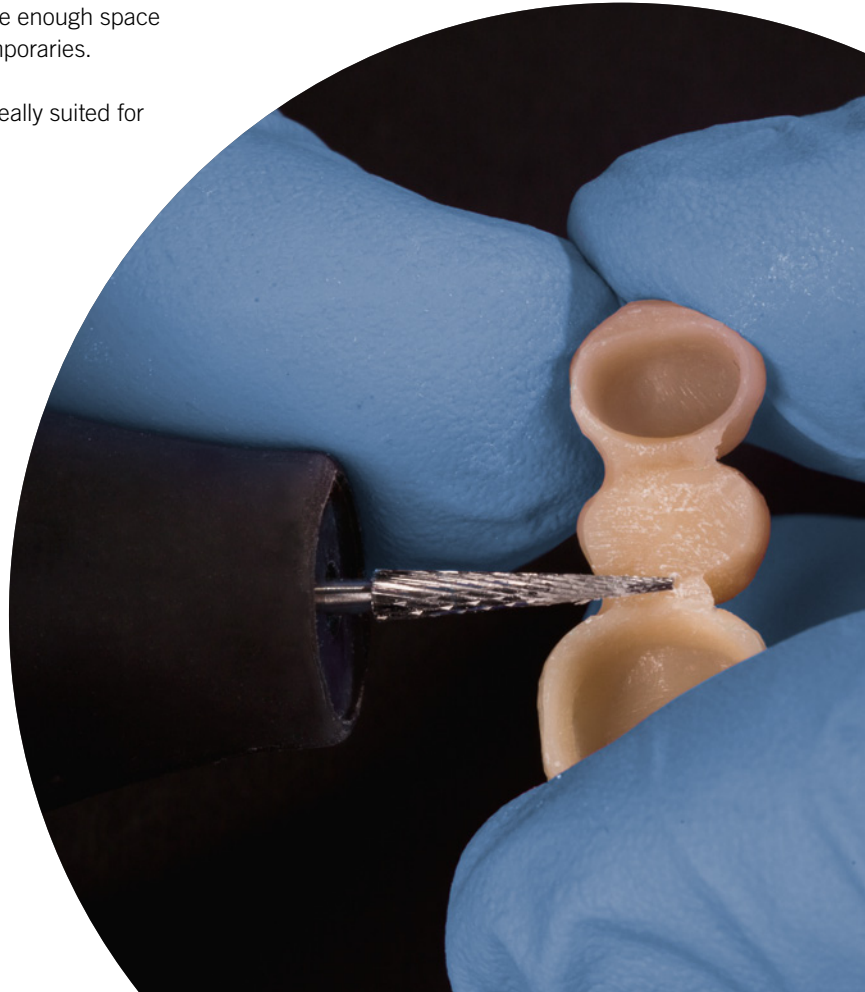


Fig. 29: Basal trimming of the interdental areas with a small conical tungsten carbide bur.



Hint: In the non-visible area the bridge pontic can also be designed as a suspended bridge element to promote better hygiene conditions.



Tip: Mark the contact point to prevent it from being accidentally wiped out (fig. 30).

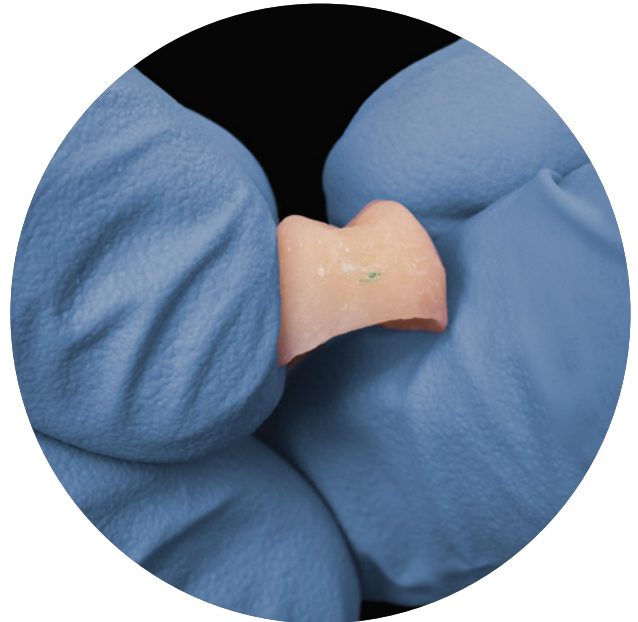
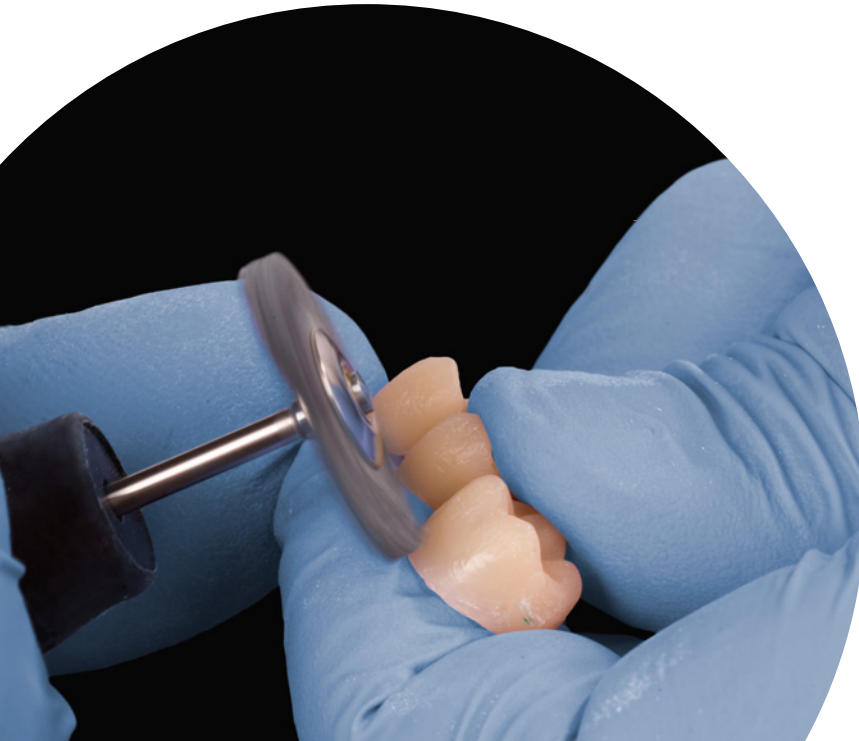
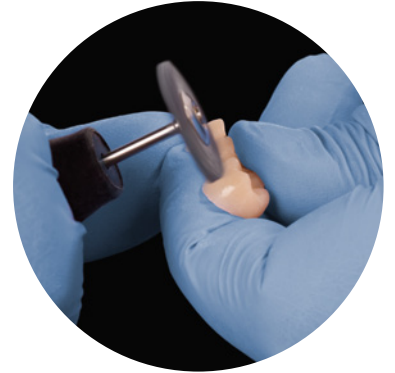


Fig. 30: Marked contact point. Remove the marking with alcohol at the end.

14

Finishing procedures

- For polishing, brushes and buffing wheels are suitable. Depending on the provisional material they can be used without polishing pastes.
- Work step by step (fig. 31–33): Hard brush for pre-polishing, soft brush for gloss, dry woolen buffing wheel for the final gloss.
- Always use brushes and buffing wheels under constant dabbing and circling movements in all directions on the provisional restoration (rpm 3.000–5.000).
- Too high pressure and too little movement can generate high local frictional heat, resulting in melting and smearing of the composite material.



Tip: Always cover the crown lumina with the fingers during polishing with brushes or buffing wheels (fig. 32) to avoid that the bristles of the polishing brush catch the rim and hurl away the provisional or damage its margins.

Fig. 32: Cover the lumina with the fingers, especially when working in the marginal area.

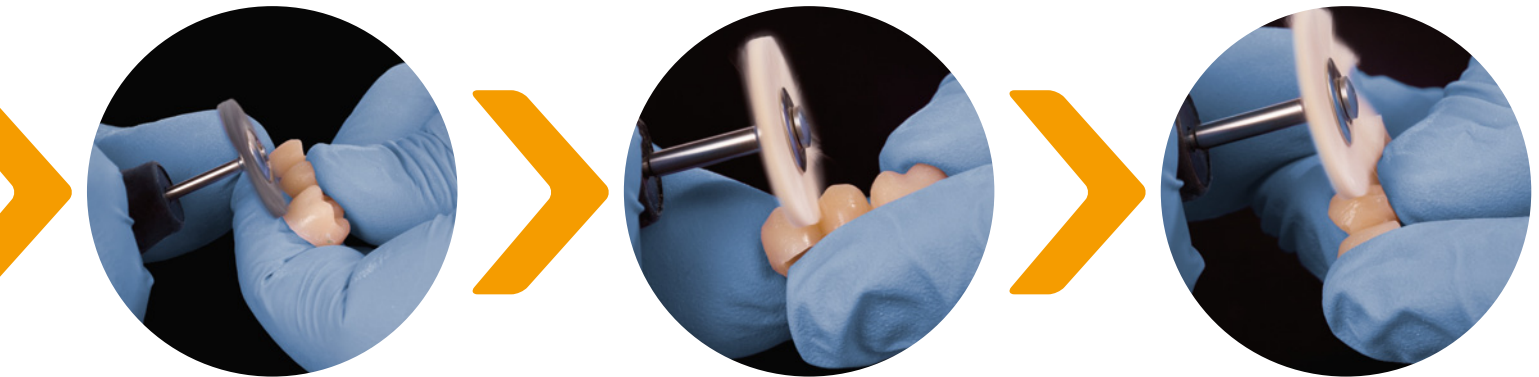

Fig. 31: Step by step: First pre-polishing with the hard brush, afterwards polishing with a soft brush. The lumina are always covered with the fingers.



Hint: Polishing pastes can contain oils or waxes which can remain as remnants on the surface of the provisional and need to be removed in a second step. Moreover they can adapt to surface roughnesses or small porosities, negatively affecting the aesthetics. Too long or intensive polishing can generate high local heat development and thus seal the incorporations in the melted composite surface. Such sealed polish residues can only be removed through further time-consuming grinding.

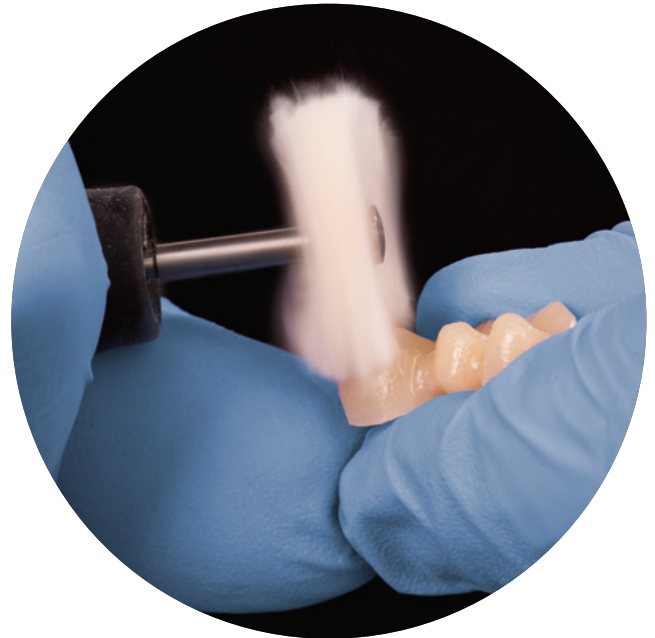

Fig. 33: Final polishing with a dry woolen buffing wheel. Again the crown lumina are covered with the fingers.

15

Final try-in

- Clean the inside and outside surfaces of the finished provisional.
- Intraoral try-in: Check the marginal fit, approximal and interdental areas, as well as occlusion and articulation.
- During checking the interproximal contacts the provisional should be properly fixated, e.g. with a big ball-shaped plugger (fig. 34).



Tip: To avoid dentine hypersensitivity a desensitizer, e.g. GLUMA Desensitizer PowerGel (fig. 35), can be applied on the prepared teeth prior to insertion of the temporary restoration.

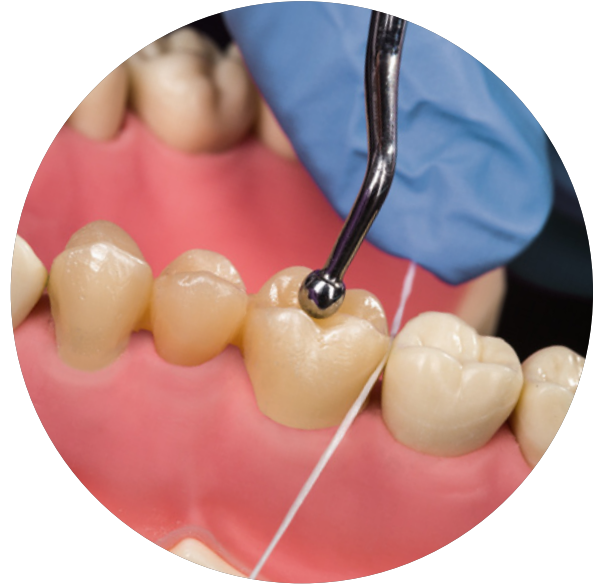

Fig. 34: Fixation of the provisional with a big ball-shaped plugger during checking the interproximal contact with dental floss.



Fig. 35: Gluma Desensitizer PowerGel for the treatment of hypersensitive dentine.

Temporary cementation

- Create a relatively dry working field.
- Clean and dry the provisional.
- Fill the cement into the crown lumina.
- For small restorations, e.g. inlays, the cement can also be applied directly into the cavity.
- Use a slight surplus of cement for insertion. Sparse cement may result in quick loss of retention of the provisional restoration.
- After correct placement of the restoration on the prepared teeth, let the patient bite together for final adjustment – either on cotton wool rolls on both sides or without any.



Hint: When planning adhesive cementation of the final restoration, an eugenol-free cement for the insertion of the temporary is emphasized. Eugenol residues might compromise the adhesive bonding.



Tip: Use a ready-to-use one-component cement, like PreVISION Cem (fig. 36) to save time. As PreVISION Cem is moisture-activated the prepared teeth need to be slightly moist for the insertion process. The provisional itself should be dry.



Fig. 36: PreVISION Cem a ready-to-use, eugenol-free cement for the temporary cementation.

17

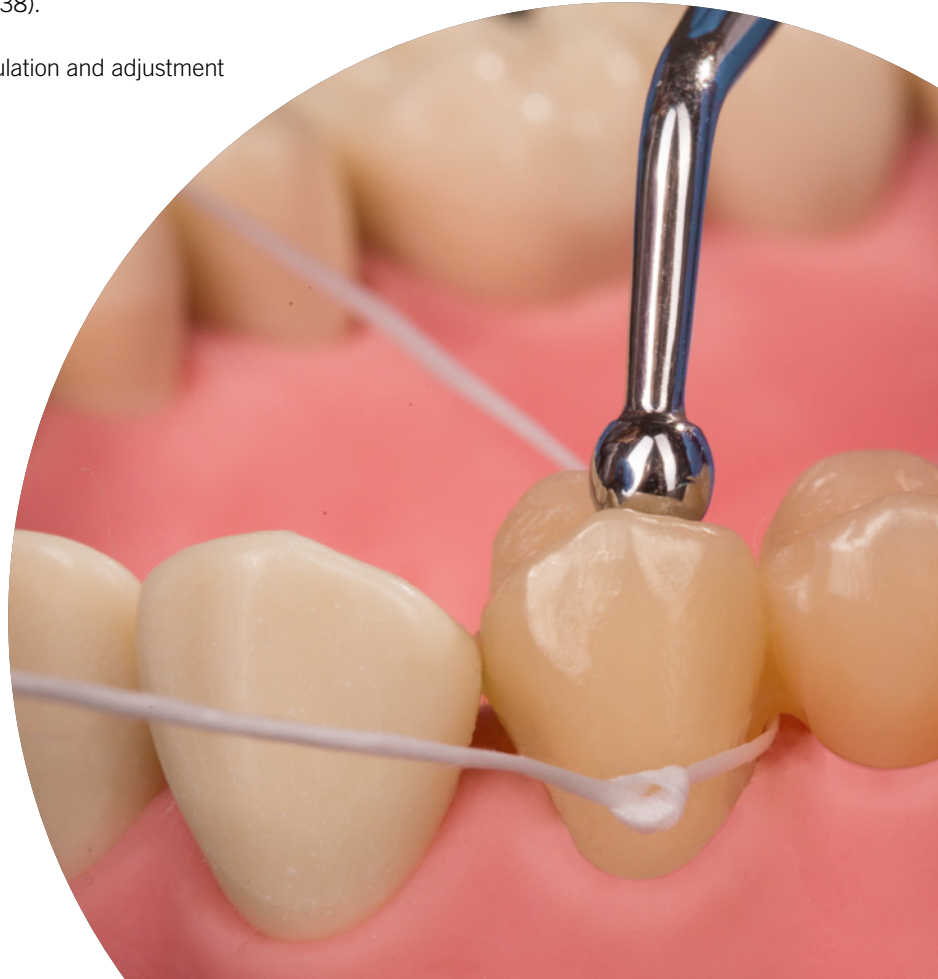
Excess removal

- After completion of setting the excess cement can be easily removed.
- Thorough removal of all excess cement to avoid gingival inflammation.
- Proper occlusal fixation of the temporary restoration during the cleaning process is emphasized, e.g. with a big ball-shaped plugger (fig. 37–38).
- Final check of occlusion and articulation and adjustment when necessary.



Tip: For cleaning underneath a pontic bridge part, make a knot in the dental floss and move it back and forth under the pontic (fig. 37).

Fig. 37: A knot in the dental floss facilitates the cleaning underneath the pontic bridge part. During the cleaning the provisional is fixed with a big ball-shaped plugger.





Tip: After cleaning in the approximal area remove the dental floss sideways underneath the contact point instead of pulling it out in the occlusal direction.

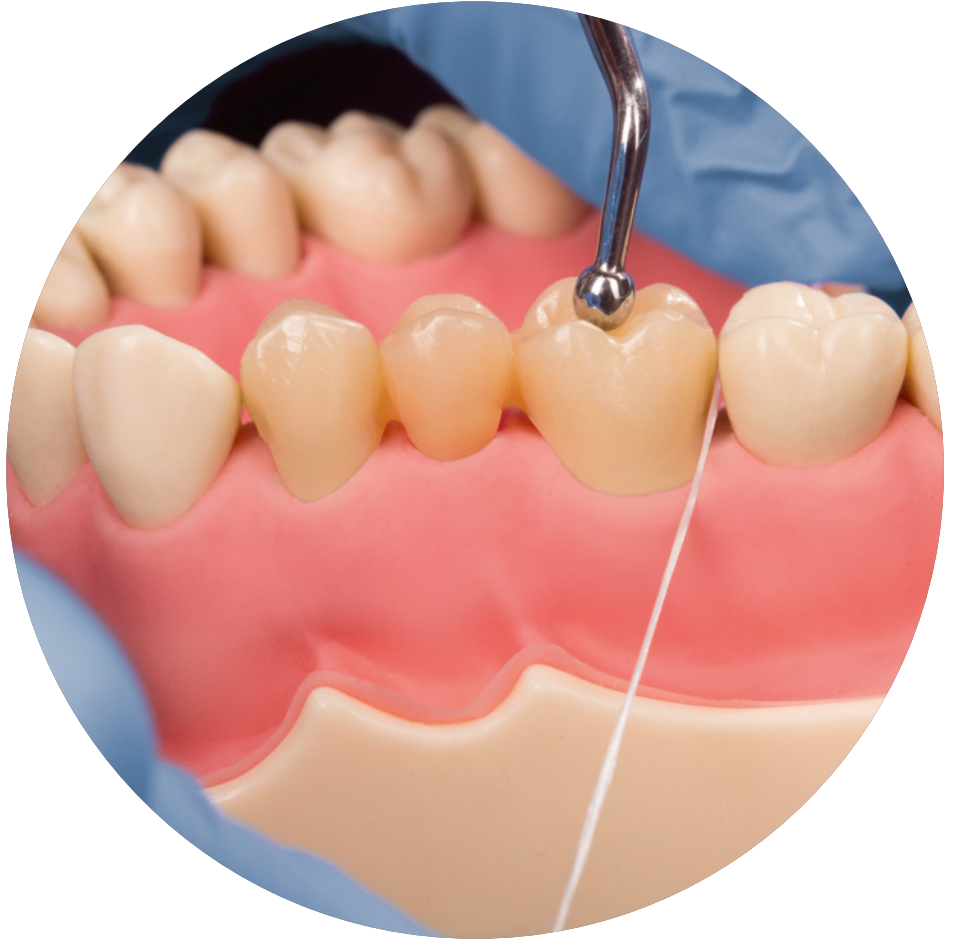

Fig. 38: Final check of approximal contact points.

FAQs

Is the smear layer on the surface directly after the fabrication of the provisional normal?

Yes, the presence of oxygen during the polymerization of light- or chemically curing dental composites inhibits the polymerization at the surface. Result is a superficial sticky layer which is called oxygen inhibition layer.

Do I need to remove the oxygen inhibition layer?

Prior to the excess removal the sticky smear layer should be removed with alcohol to facilitate the trimming procedure. Furthermore a residual smear layer might result in quick discoloration of the provisional and an unpleasant taste for the patient.

How do I repair a small imperfection directly after fabrication?

As long as the oxygen inhibition layer (smear layer) is existing on the temporary, extra material (provisional c&b material or a flowable, lightcuring composite material) can be simply added to repair small voids or imperfections.

How do I repair a provisional restoration made from a composite based C&B material that is fractured during the wearing period?

A provisional can also serve as a clinical verification of the restoration design. Thus, a fractured provisional can be an indication to critically examine the design of the preparation and of the temporary restoration once again.

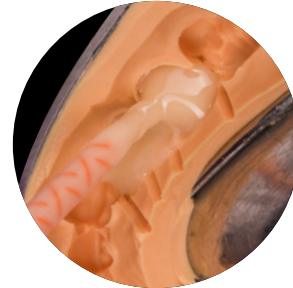For the repair, roughen the surface of the fracture area with a fine cross-cut carbide bur to increase mechanical retention. To additionally enhance the adhesion, apply and light-cure a bonding agent, e.g. iBond Universal, according to the instructions for use. For small repairs light-curing flowable composite materials, e.g. Venus Diamond Flow, are suitable. Advantage of the flow material is its easier handling, i.e. more exact dosing and the initiation of the polymerization process via light curing. For major repairs a provisional crown and bridge material is recommended or, if necessary, the fabrication of a new provisional.

Why is it necessary to bleed the cartridge before the initial use?

Due to technical reasons the filling level of the two chambers of auto-mixing two-component provisional materials can slightly differ. Thus, most manufacturers recommend bleeding of the cartridge before the very first use to ensure both pastes are evenly delivered.

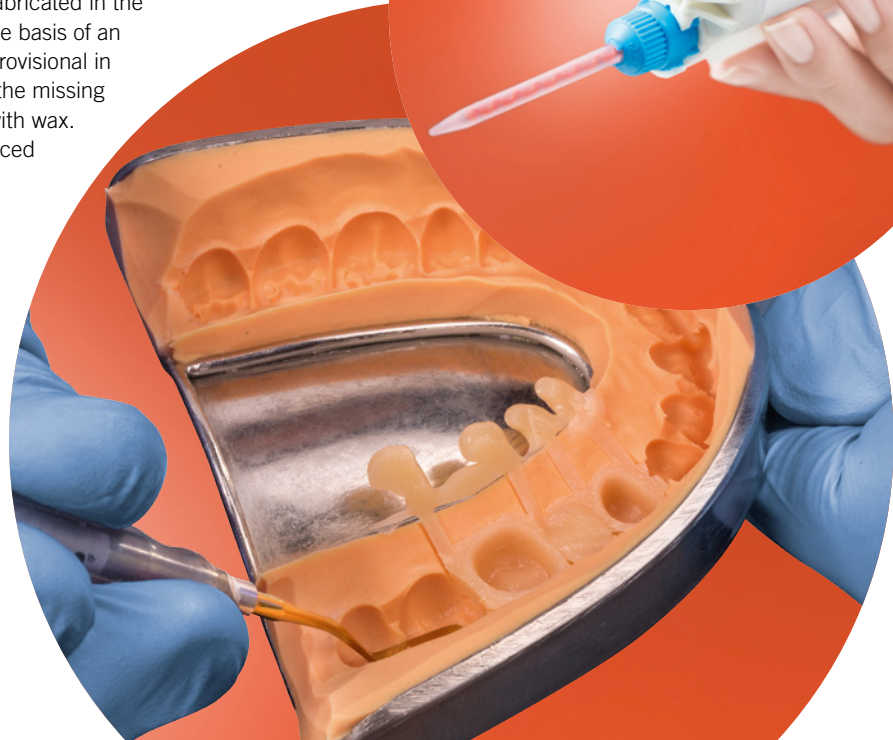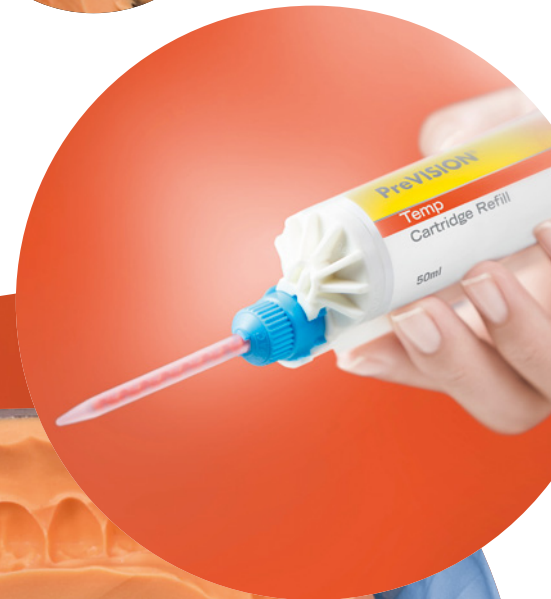Is it necessary to bleed the cartridge before each use?

No, in general this is only emphasized before the very first use. But it is recommended to discard the first pea-sized amount of material from each new mixing tip.



How do I fabricate a wide-span bridge temporary when there is no existing bridge restoration?

In that case the direct method is not appropriate. Instead either the indirect method or a mixed procedure is used. Using the indirect method, the provisional is completely fabricated in the dental laboratory by the dental technician on the basis of an anatomic model. Later, the dentist relines the provisional in the patient's mouth. In the combined method, the missing teeth are replaced by denture teeth and fixed with wax. In the deep drawing procedure a mold is produced that the dentist can use later for the fabrication of the provisional in the patient's mouth.



Hint: Please note only xantasil, PreVISION, Signum, GLUMA, iBOND and Venus are registered trademarks of Kulzer.

Notes

This image shows a single sheet of white paper with horizontal ruling lines. The lines are evenly spaced and run across the width of the page. There are no margins, text, or other markings on the paper.

This image shows a single sheet of white paper with horizontal ruling lines. The lines are evenly spaced and run across the width of the page. There are no margins, text, or other markings on the paper.

Contact in Germany

Kulzer GmbH
Leipziger Straße 2
63450 Hanau
Germany
info.dent@kulzer-dental.com

kulzer.com