

# New smile in time for wedding surpasses expectations

**Ash Soneji** describes a case that successfully combines fixed orthodontics and bleaching with the aesthetics and durability of composite edge-bonding

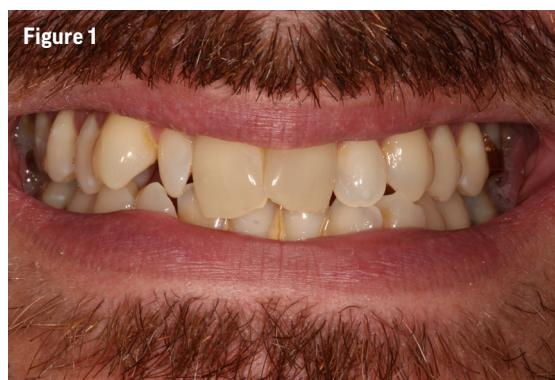

Figure 1

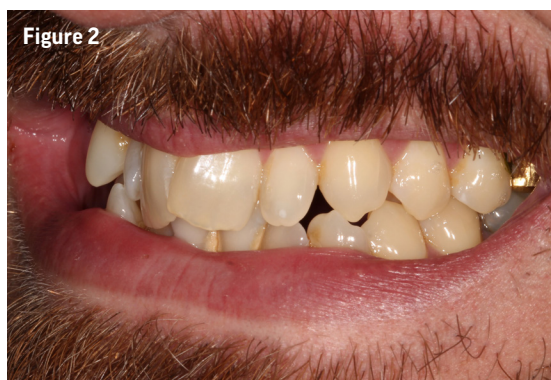

Figure 2

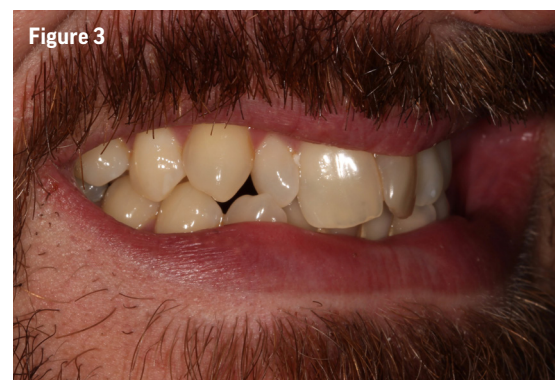

Figure 3

Figures 1-3: The patient was unhappy with the alignment, shape and colour of his teeth

## Dr Ash Soneji

Dental surgeon at Circus House  
Dental and Implant Centre in Bath



A 35-year-old male attended the practice because he was unhappy with the alignment, shape and colour of his teeth (Figures 1 to 3).

The patient wanted to correct the upper and lower crowding. He felt that having his teeth straightened and whitened would improve his smile and self-confidence for his forthcoming wedding.

## Orthodontic choices

The options presented to the patient included leaving the teeth untreated, or veneers, which would require invasive preparation. The orthodontic choices were clear aligners, fixed appliances, or a combined orthodontic and restorative approach. We also discussed referral to a specialist.

Clear aligners could potentially result in a similar outcome to fixed braces. They are discreet, but require a longer treatment time and are more expensive. Fixed appliances offered the most potential for improving the aesthetics within the patient's time constraints.

A full orthodontic and diagnostic assessment was undertaken. The patient had a class I skeletal base and a class I malocclusion, with UR2 and UL3 anterior cross bites. Severe upper arch and moderate lower arch crowding was recorded, with a lower centre shift to the left. Orthodontic treatment would de-crowd the upper and lower arches, correct the anterior cross bites and provide space for upper anterior composite build-ups.

The patient was not keen to have teeth extracted and wanted the treatment to be as minimally invasive as possible. He had set a deadline of 12 months, to achieve an improved smile in time for his wedding day.

The patient was assessed for clear aligners, but they were not suitable due to the level of crowding and required treatment time. He didn't mind having a fixed wire, so opted for dual-arch Fastbraces using clear and discreet brackets.

## Successful alignment

The patient was made aware that interproximal reduction (IPR) would be needed. Permanent fixed and removable retainers would also be required after treatment, as his teeth would continue to move.

He was advised that after alignment, additional composite bonding would be necessary. There had been differential wear on his teeth caused by the crowding.

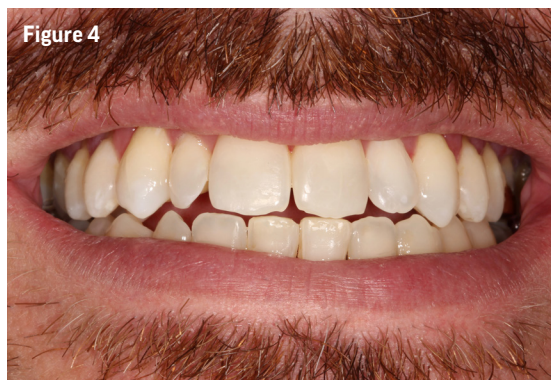

Figure 4

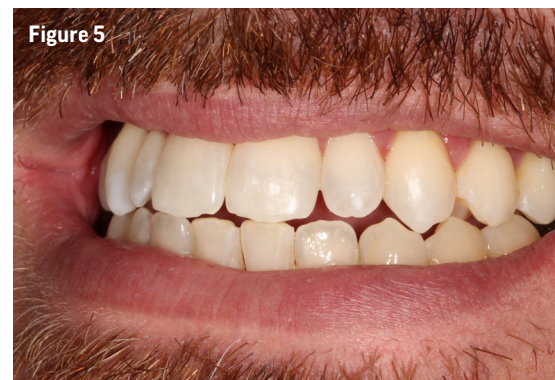

Figure 5

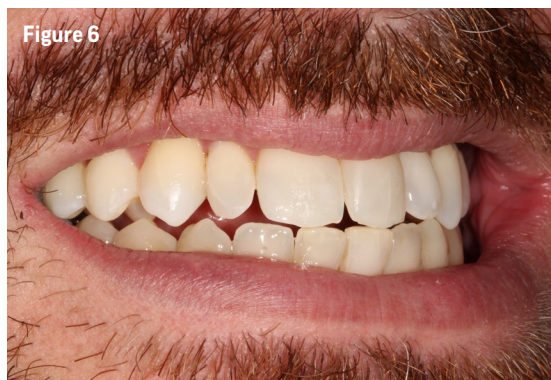

Figure 6

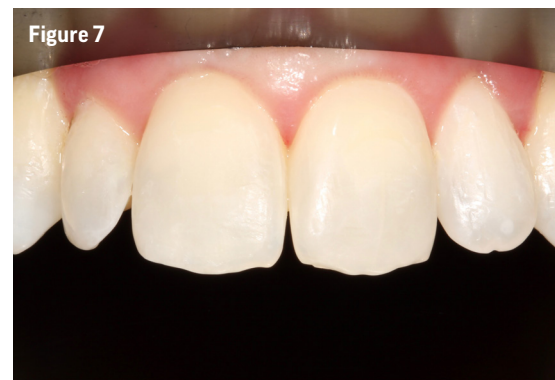

Figure 7

Figures 4-7: Alignment was completed after nine months. Following bracket removal, the patient completed home tooth whitening

Even though the teeth would be in the correct orthodontic position after treatment, they still would not look straight.

Composite bonding would be needed on the upper right lateral incisor due to its shape and diminutive size, and on the worn edges of the upper central incisors.

The orthodontic treatment was carried out under the mentorship of Dr George Mexius, a highly experienced provider of Fastbraces. Under his guidance, the brackets were positioned freehand, in accordance with Fastbraces protocol.

Kulzer Ibond Self Etch was used to attach the brackets. The adhesive has reliable bond strength and is easy to use.

An intraoral scan was taken with the brackets in position. The laboratory digitally debonds the brackets and produces Essix retainers.

The retainers can then be fitted at the same time as debond and the placement of the fixed retainer. This helps reduce the number of appointments and the risk of immediate relapse.

The patient was seen at six to eight weeks for review and minor IPR was carried out during the process to allow stubborn teeth to rotate.

Alignment was completed after nine months and the patient approved the result.

## Whitening and retention

Following bracket removal, the patient completed home tooth whitening with Whitewash Laboratories Professional 6% hydrogen peroxide teeth whitening gel using Essix retainers (Figures 4 to 7).

It would have been more beneficial to use a whitening tray, but, due to the distance the patient travelled for appointments, this was not possible.

The retainers were used with specific instruction on the quantity of bleach to apply to prevent extrusion and gingival irritation. The final shade was A1.

The upper and lower fixed retainer wires were bonded. To ensure correct positioning, the retainer wires were fabricated using a pre-made jig, with a pre-formed orthodontic wire for accuracy. Floss was

used to hold the wire tightly between the contacts and the teeth were etched with a 36% phosphoric acid etch gel and bonded using a total-etch dental adhesive.

A thin layer of Kulzer Venus Diamond Flow was placed at a sufficient thickness to cover and secure the wires, then light-cured.

### Composite versatility and strength

A digital wax-up was created from the intraoral scan (Figure 8). After approval by the patient, a 3D model was printed and a chairside stent fabricated, using a light and medium body silicone dental impression material. A mock-up was placed directly in the mouth using composite developed for temporary restorations (Figure 9).

Following confirmation that the patient was happy with the mock-up, the stent was used to create the final restorations. The edge bonding was completed on the UR2, UR1, UL1 and UL2, as per the digital wax-up (Figure 10). The teeth were isolated with rubber dam, dam inversion and floss ligatures.

Kulzer Venus Diamond Flow A1 shade was used to help build up the palatal shells and fill in voids in the interproximal areas.

The composite was not layered and the single shade of Kulzer Venus Diamond A1 was selected. As multiple teeth were restored, this method ensured they matched. It also achieved the aesthetic result the patient wanted, by creating a bright, but uniform, smile without too much translucency. Characterisation tints were not applied.

Venus Diamond has a wide range of shades, which are equally good used as a mono shade or as part of a layering technique. The material adapts perfectly to the colour of the surrounding teeth, and is reliable and versatile, particularly when changing the tooth shape, as with this patient's upper right lateral incisor.

Venus Diamond also has exceptional strength, durability and easy handling, with consistent polishability, producing a high-gloss finish.

### Minimally invasive result

The composite was shaped with Kulzer Signum Liquid. The modelling resin helps to adapt the material more easily, allowing the restoration to be sculpted beautifully, reducing the amount of finishing and polishing required. The restorations were given a final polish using Sof-Lex discs, silicone finishing points, a felt-coated buffing disc and aluminium oxide polishing paste.

Composite bonding allowed successful completion of this post-orthodontic case by achieving an aesthetic, minimally invasive, same-day result.

The material was used alongside digital technology to provide cutting-edge treatment and a 'wow factor' for the patient.

The outcome surpassed his expectations and met the deadline (Figure 11). He was delighted with his smile on his wedding day (Figures 12a and 12b). **D**

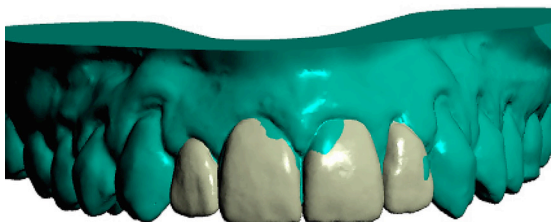


Figure 8: A digital wax-up was created from the intraoral scan

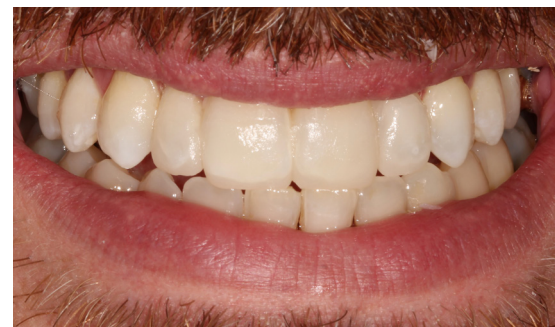

Figure 9: A mock-up was placed directly in the mouth using composite developed for temporary restorations

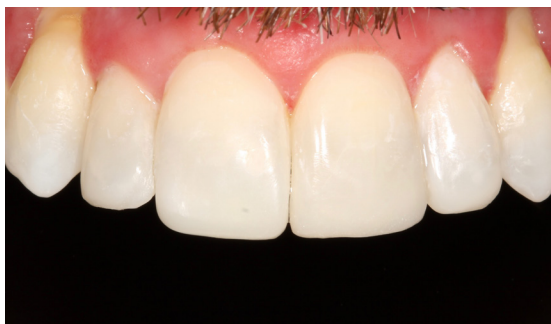

Figure 10: Kulzer Venus Diamond Flow, A1 shade and Kulzer Venus Diamond A1 were used to restore the UR2, UR1, UL1 and UL2

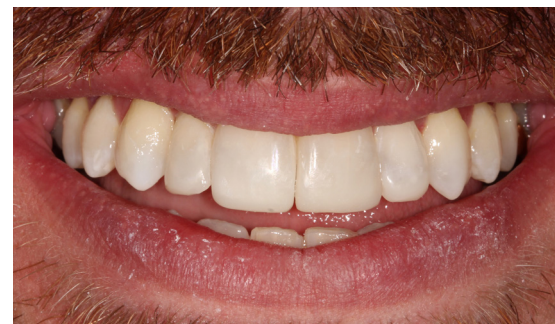

Figure 11: The outcome surpassed the patient's expectations and met the deadline



Figures 12a and 12b: Before and after. The patient was delighted with his smile on his wedding day

