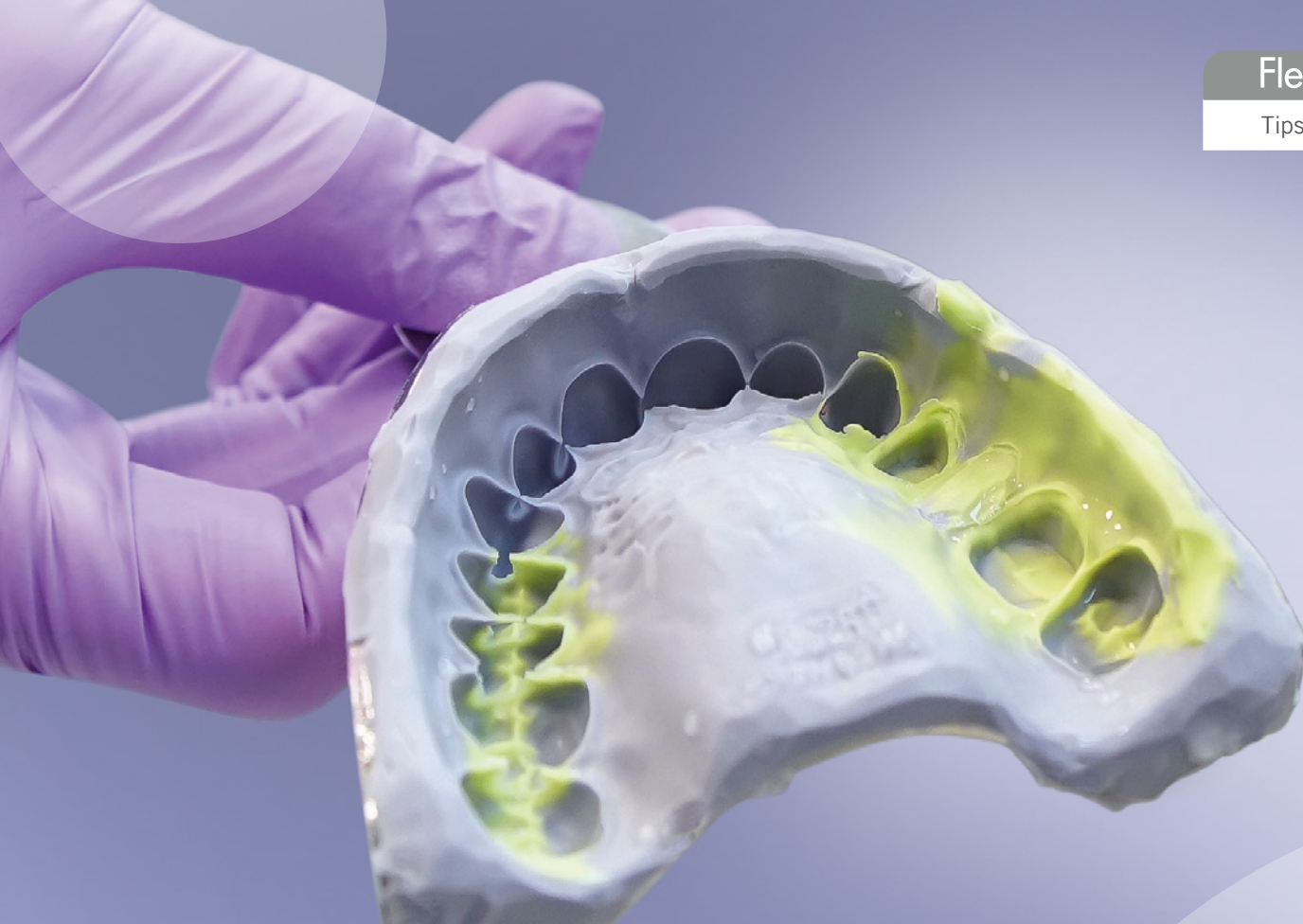

Flexitime®

Tips & Tricks



Tips & Tricks

One-step impression technique

Giving a hand to oral health.

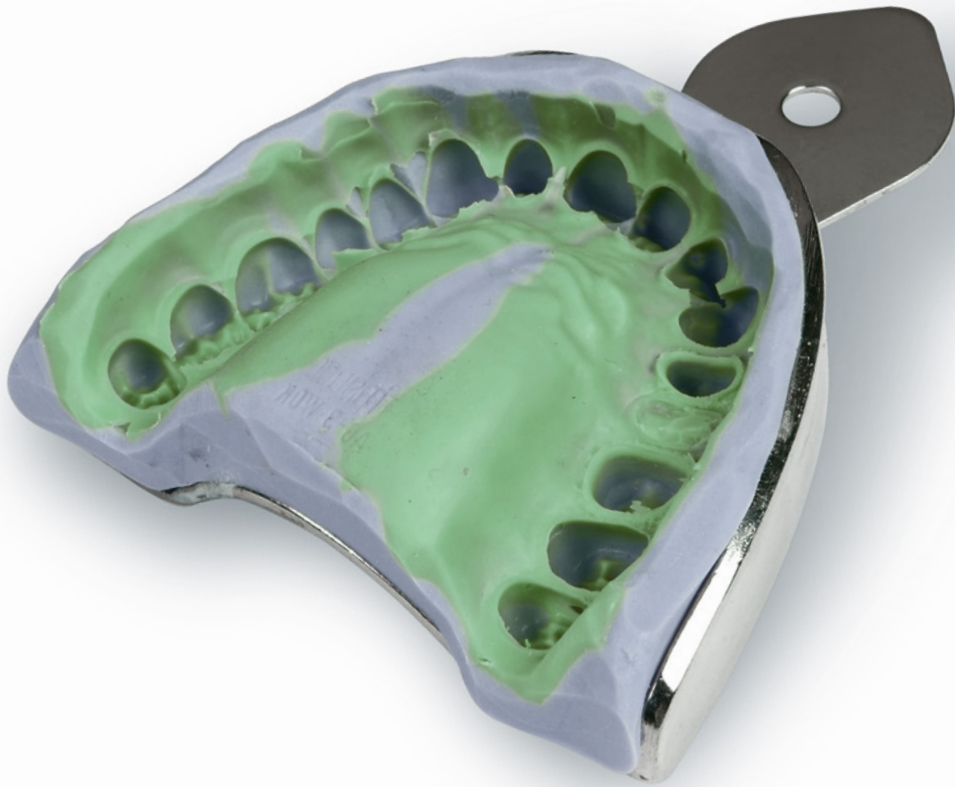


KULZER
MITSUI CHEMICALS GROUP

Content

01	One-step impression techniques	p. 06	08	Retraction cords	p. 20
02	One-step versus two-step impression techniques	p. 08	09	Retraction cord techniques	p. 22
03	One-step techniques for the precision impression	p. 11	10	Vasoconstrictors and astringents	p. 24
04	Selection of impression tray	p. 13	11	Retraction pastes and gels	p. 26
05	Selection of tray size	p. 14	12	Tray adhesive	p. 27
06	Damming and blocking out impression trays	p. 16	13	Double-mix technique	p. 28
07	Soft tissue management	p. 19	14	Sandwich technique	p. 30

15**Monophase technique p. 31****16****Patient positioning and tray insertion p. 32****17****Working time and intraoral setting time p. 34****18****Removal of the impression p. 35****19****Assessment of the impression p. 36****20****Cleaning and disinfecting the impression p. 37****21****Storage and transport of the impression p. 38****22****Opposing arch impression, bite registration and provisional p. 39**



Preface

The impression is one of the first steps in the manufacturing chain of a dental restoration and can be a crucial factor for a successful treatment. Potential errors in the impression can impair the entire manufacturing process. Thus error-free, detailed and dimensionally accurate impressions are essential for the success.

Aim of Kulzer is not only to supply dentists and dental technicians with reliable materials but also to be a competent partner for dental questions. Hence, based on the extensive experience and cooperation with dental professionals a series of tips and tricks booklets around the topic of precision impression taking has been created.

The present tips and tricks guide deals with the one-step impression techniques in particular as well as the handling of impression materials and aids in general, and comprises practical advice on the impression taking procedure.



Dr. med. dent. Andrea Leyer
Global Scientific Affairs Manager
Hanau (Germany)



01

One-step impression techniques

Even in the age of digitalization the conventional impression belongs to the standard repertoire in the dental office and one-step impression techniques are quite frequently used. Depending on the impression material employed, one-step techniques can be used for anatomical impressions (fig. 1) such as opposing jaw impressions, or they can be used for precision impressions (fig. 2).

For anatomical impressions, alginates or A-silicones that are especially designed for the requirements of anatomical impressions (the so called alginate substitutes) are used.

For useful Tips & Tricks on situation impressions take a look at our Alginate Guideline brochure.



kulzer.com/alginate-guide



Brochure Alginates – Guideline for Taking Perfect Situation Impressions

One-step precision impressions for the fabrication of fixed dental restorations (e.g. inlay/onlay, crown, bridge) are commonly taken with A-silicones or polyether.

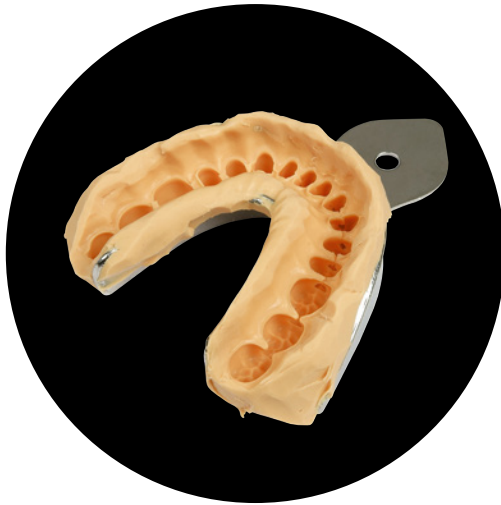

Fig. 1: Opposing jaw impression with the alginate substitute xantasil (Kulzer).

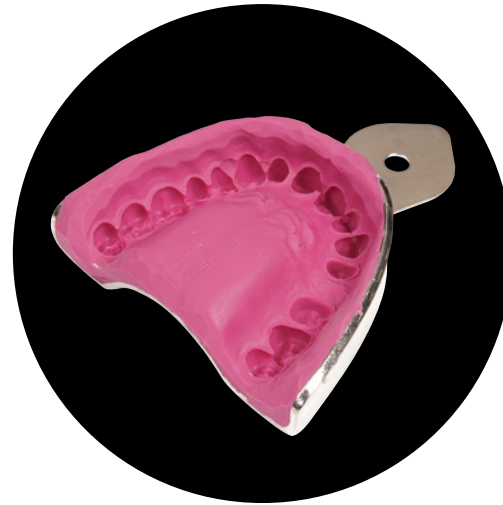

Fig. 2: One-step precision impression with the A-silicone Flexitime Monophase (Kulzer).

02

One-step versus two-step impression techniques

In contrast to the two-step impression technique, the one-step techniques are almost pressureless impression techniques. Furthermore, during the one-step impression process all the employed materials are in the plastic stage, thus reducing the risk of developing permanent deformation in the impression. On the other hand, no significant hydraulic pressure occurs during the one-step impression to push the impression material into hard-to-reach areas. This may result in flow defects in the impression, especially when more or less larger undercuts are present. In particular, when taking a precision impression of a subgingivally located preparation margin, the hydraulic pressure of the one-step impression may be too weak to adequately push the light bodied impression material into the hard-to-reach sulcus. In this case, the two-step impression technique might be more suitable.

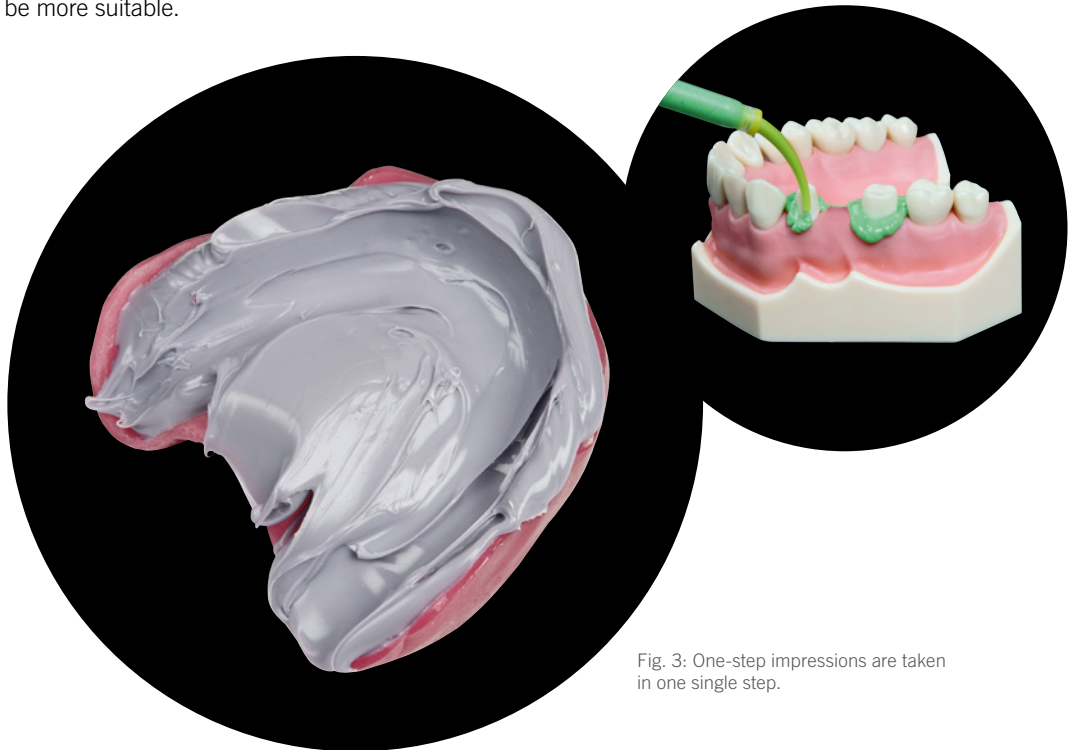


Fig. 3: One-step impressions are taken in one single step.

Advantage of the one-step over the two-step technique is, that the impression is taken in one single step and is less labour-intensive (fig. 3). Time-consuming steps, such as cutting out the initial impression (fig. 4 & 5), are not necessary during one-step impression techniques. In principal, one-step impression techniques are known as relatively easy, fast and less error-prone.

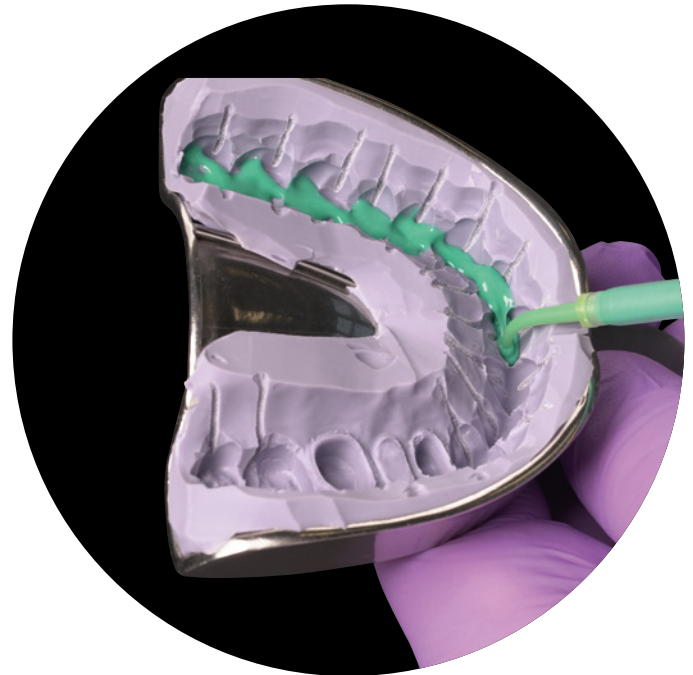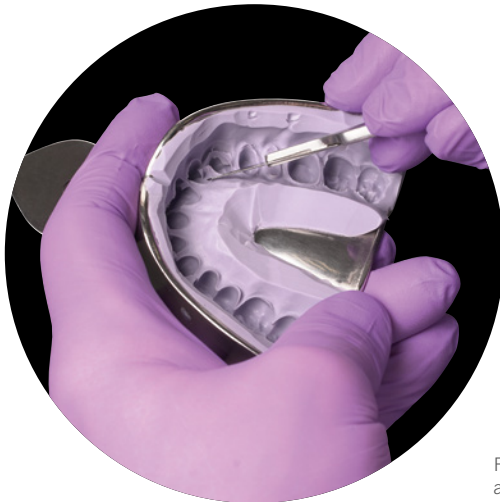


Fig. 4 & 5: For two-step impressions, the initial impression is cut out in the first step and the actual corrective impression is taken in a second step.



Tip: To capture a subgingival preparation margin the two-step impression technique may be more suitable due to its high hydraulic pressure (fig. 6).

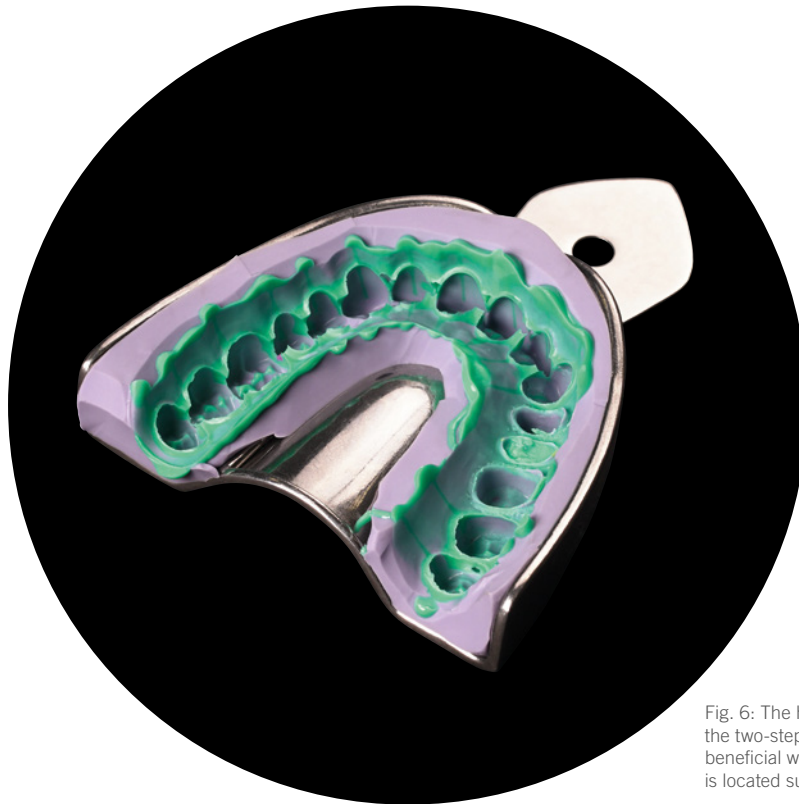

Fig. 6: The high hydraulic pressure of the two-step impression can be beneficial when the preparation margin is located subgingivally.

03

One-step techniques for the precision impression

In general, one-step impression techniques for the precision impression can be divided into single-stage, two-phase techniques and the mono-phase technique (single-stage, single-phase).

For single-stage, two-phase impression techniques two materials of different viscosity are combined with each other in one single step (fig. 7): a material of higher viscosity for filling the impression tray and a material of lower viscosity for syringing the teeth. Immediately after the teeth are syringed, the filled tray is inserted into the mouth and the two phases mix up and set jointly. This is usually referred to as double mix technique. In contrast, if the wash material is applied onto the tray material as a second layer, the technique may be referred to as sandwich technique (fig. 8).



Hint: When using a kneadable tray material, the wash material should be applied as a second layer onto the tray material (fig. 8). Otherwise, it may be displaced too strongly by the putty material.

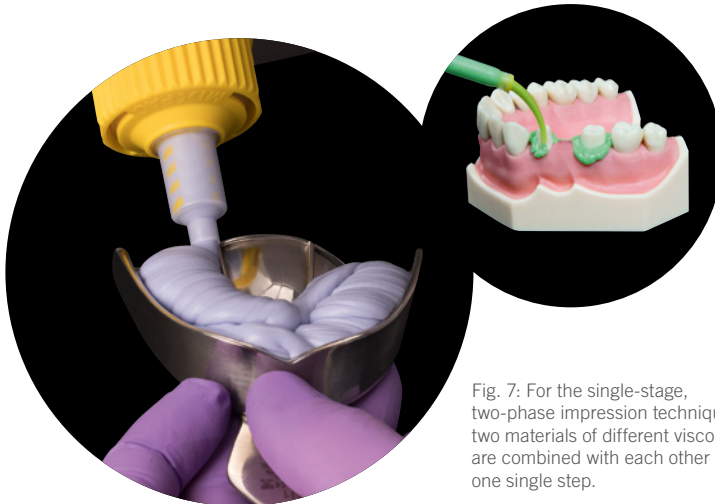


Fig. 7: For the single-stage, two-phase impression technique, two materials of different viscosity are combined with each other in one single step.

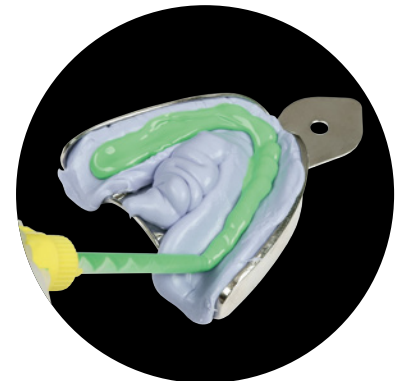

Fig. 8: For the sandwich impression, a layer of wash material is applied onto the tray material.

Whereas, the monophasic technique is a single-stage, single-phase impression technique where only one material of one consistency is applied (fig. 9). Here, usually a medium viscous impression material is used for filling the tray as well as for syringing the teeth. The monophasic technique is a relatively easy and quick impression technique. It is particularly suitable when having supragingival preparations or for transfer- and implant impressions.

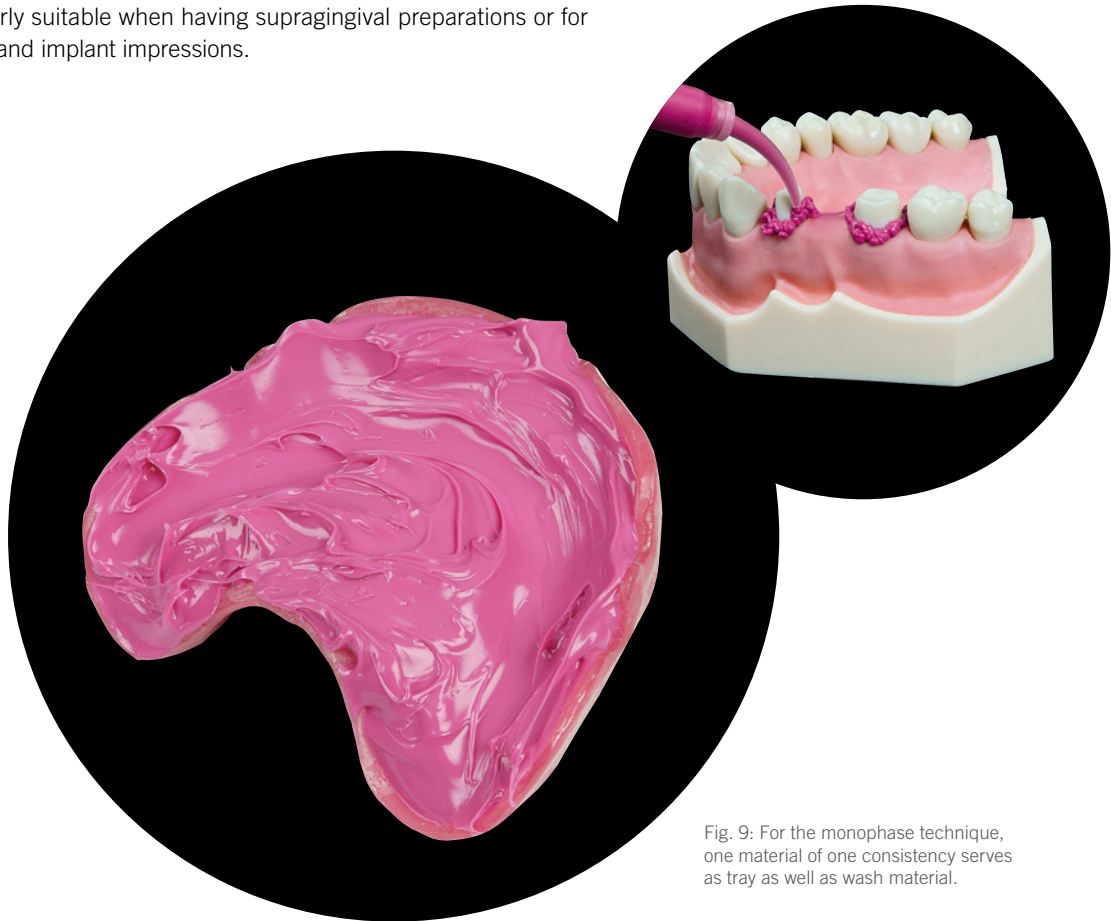

Fig. 9: For the monophasic technique, one material of one consistency serves as tray as well as wash material.

04

Selection of impression tray

The impression tray is, so to speak, the “backbone” of the impression and thus plays a very important role concerning the quality of the impression. An adequate impression tray should be rigid, i.e. torsion-resistant. In contrast to the two-step impression technique, hardly any substantial hydraulic pressure is achieved during one-step techniques. Therefore, the usage of an individual tray is recommended for one-step techniques to achieve an equal material layer thickness and at least some hydraulic pressure. However, stock trays can also be used.



Fig. 10: Trays suggested for highly viscous impression materials (heavy tray): e.g. individual tray, Border-Lock tray, Rim-Lock tray, non-perforated Ehrlicke tray.



Fig. 11: Trays suggested for kneadable materials (putty): e.g. Aesculap Jescoform tray, Rim-Lock tray, perforated Ehrlicke tray, unperforated Ehrlicke tray.



Hint: When using a highly viscous impression material (heavy tray), an unperforated tray should be chosen (fig. 10).



Hint: When using a kneadable impression material (putty), perforated as well as non-perforated impression trays can be used (fig. 11).

05

Selection of tray size

The size of the tray depends on the clinical situation. Especially when having large undercuts of the jaw or strong divergence respectively convergence of the remaining teeth, particular attention must be paid to the size of the tray. Also in the area of the largest undercut (later the section that undergoes the highest compression) sufficient distance between tray wall and tooth equator needs to be available (fig. 12 & 13), in order to ensure an easy mouth removal without permanent deformation of the impression material. Too low material thickness results in a very high compression of the impression material that cannot completely recover.



Tip: Rule of thumb for sufficient material thickness: Distance between tooth equator and tray wall needs to be at least twice as big as the extent of the undercut (fig. 12). That goes along with a later compression of the impression material by only one third (fig. 13) which allows a complete recovery of the impression material.

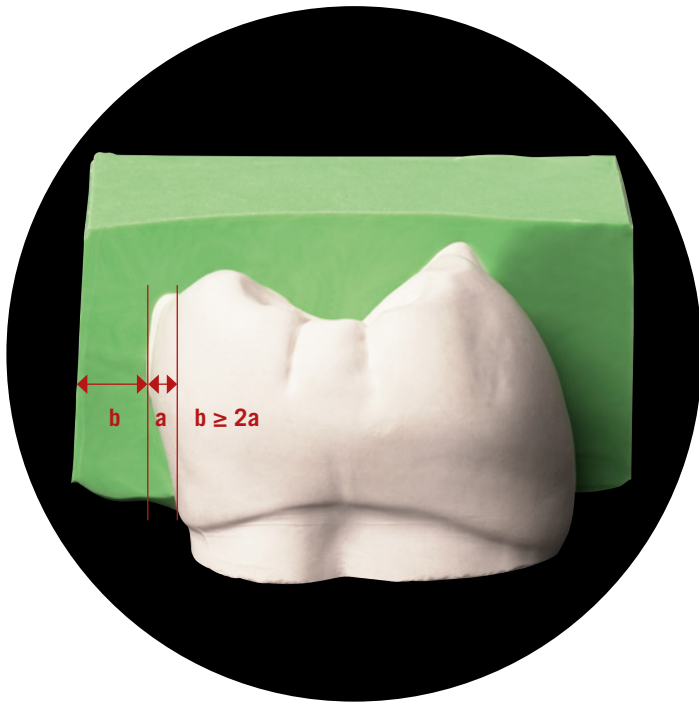


Fig. 12: The distance between tooth equator and tray wall (b) should be at least twice as big as the extent of the undercut (a).

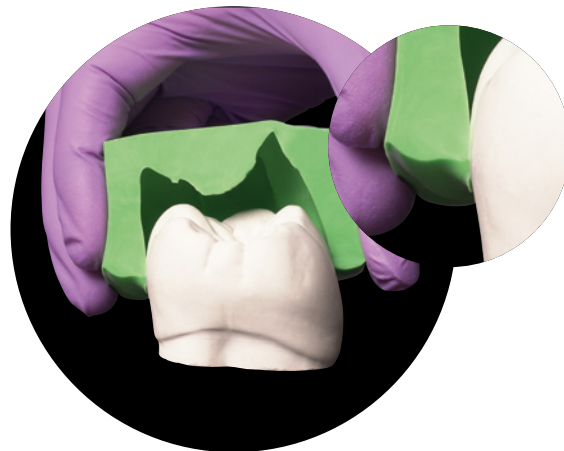


Fig. 13: Highest compression in the area of the tooth equator



Hint: For maxillary trays the distance in the buccal area, for mandibular trays the distance in the lingual area is often too small (fig. 14). At the first glance, the tray seems to be well fitting but indeed the jaw can have large undercuts. Thus, in the upper jaw a bigger tray size is to be preferred as the undercuts are buccally located. In the lower jaw a smaller tray size might be more advantageous as the undercuts are lingually located. However, there should be a minimal distance of at least 3 mm between tray wall and jaw (fig. 15).



Fig. 14: Buccally the space would be sufficient, but lingually the tray sits far too close.

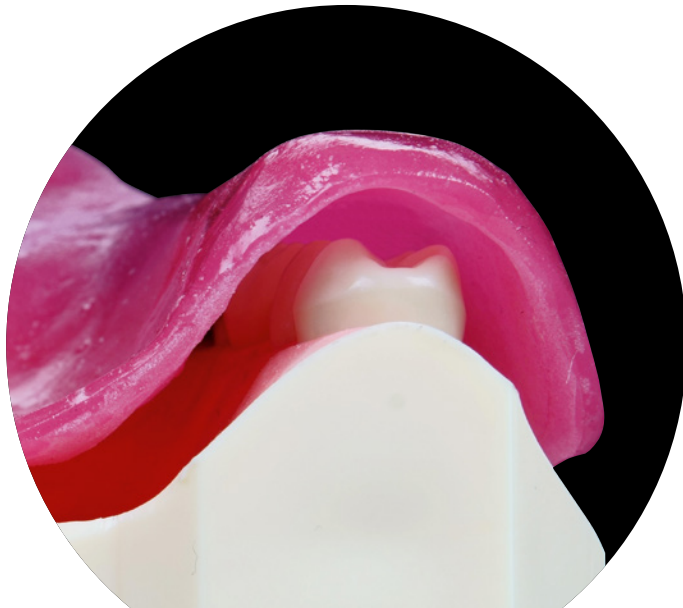

Fig. 15: Sufficient distance to the tray wall on both sides

06

Damming and blocking out impression trays

Damming can become necessary in serial trays without boundary in the dorsal area (e.g. Rim-Lock or Ehrlicke tray). Dorsal damming of the impression tray inhibits leakage of the impression material from the impression tray in the distal region. On the one hand, it can be prevented that surplus impression material flows into the patient's throat and induces a gag reflex. On the other hand, flow defects in the dorsal area can be avoided: In trays without dorsal damming the impression material can flow off distally, so that the terminal teeth are not fully captured by the impression material (fig. 16).

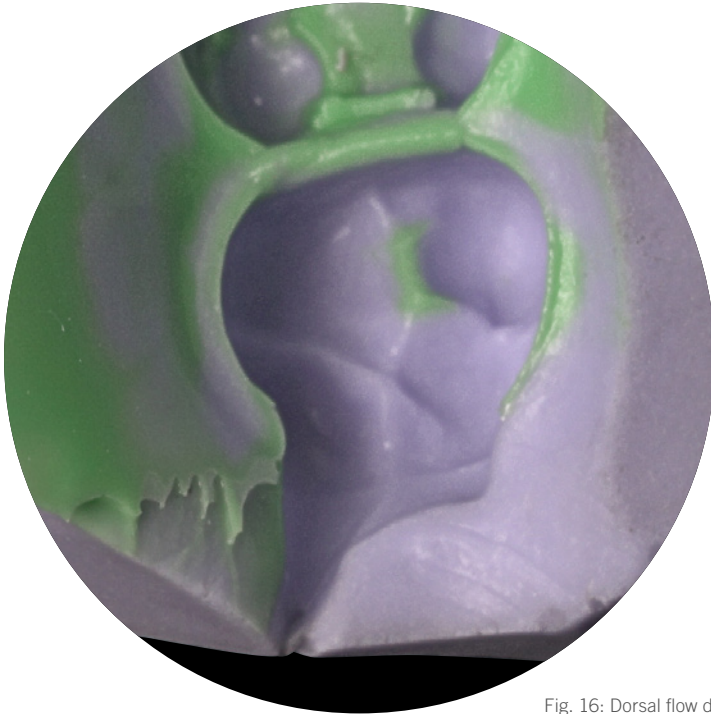


Fig. 16: Dorsal flow defect.

For blocking out in the dorsal area, tray plastics or thermoplastic materials can be used. Blocking out in the palatal area is done with kneadable impression materials.

This is often necessary for prefabricated maxillary trays, when the palate of the patient is high and narrow.



Hint: The prepared tray should be tried on in the patient's mouth to avoid that the blocked-out area is too high. The teeth need to be completely captured by the impression tray despite the blocked-out area.



Tip: To avoid pushing the tray against the teeth during impression taking, occlusal stops can be positioned in the tray at suitable sites (i.e. not in the area of the prepared teeth).

Without a blocked-out palate, the impression material flows off into that “cavity”, that does not offer any resistance. Thus, no adequate hydraulic pressure can be achieved, which is necessary to push the impression material into hard-to-reach areas of the jaw. The consequence are deep grooves that reach from the palatal tooth necks of the posterior teeth to the palate (fig. 17).



Fig. 17: Palatal flow defects in the posterior region.



Hint: If present, extensive undercuts in the mouth (e.g. suspended bridge) should be blocked out with an appropriate wax prior to impression taking. Remember to remove the wax afterwards.



Hint: If a composite build-up filling was placed or a methacrylate-based provisional was fabricated in the same session, the smear layer needs to be removed with a cotton pellet soaked in alcohol prior to impression taking. Otherwise, the setting reaction of the impression material can be affected.

07

Soft tissue management

The marginal quality and thus the long-term success of a fixed restoration is significantly influenced by the reproduction of the preparation margin in the impression. Even though modern impression materials have a high degree of hydrophilicity and flowability, adequate isolation and clear depiction of the preparation margin, especially when subgingivally located, are essential (fig. 18 & 19). To enable the inflow of the impression material into the sulcus, the gingival tissue needs to be temporarily retracted and fluids such as blood or sulcus fluid have to be kept away.

In principal, mechanical, chemical and surgical methods are available for the displacement of the gingiva. The surgical procedure, i.e. the gingivectomy, is an irreversible intervention, and thus not suitable for a temporary retraction of the gingival tissue.

As mechanical aids for the temporary sulcus opening retraction, cords, gels, pastes and special silicones are available. As chemical components for hemostasis, astringents and vasoconstrictors are in use. The most common method seems to be the combined chemo-mechanical technique. Besides the clinical situation, soft tissue management especially depends on the individual preference of the clinician.



Tip: When having a hard to control bleeding, it is recommended to take the impression in a separate appointment at a later stage (about 8–10 days later). The follow-up appointment should not be too early as the granulation tissue during the healing phase tends to bleed easily.

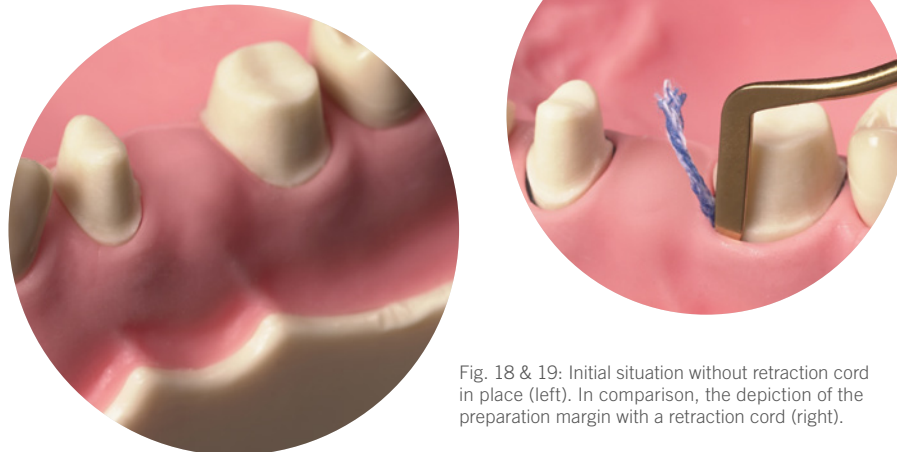


Fig. 18 & 19: Initial situation without retraction cord in place (left). In comparison, the depiction of the preparation margin with a retraction cord (right).

08

Retraction cords

Retraction cords are usually made of cotton, as cotton absorbs well. They are available in several diameters and various types, i.e. twisted, braided or woven. Furthermore, a distinction is made between impregnated and non-impregnated cords. Impregnated cords are already pretreated by the manufacturer with a chemical agent for hemostasis. As the active agent in the impregnated cord is present in the dried form, sufficient sulcus liquid needs to be present for its elution.



Tip: After having soaked the cords, slightly dry them before the application in the mouth (fig. 22).




Fig. 20 & 21: Impregnation of a non-impregnated retraction cord.

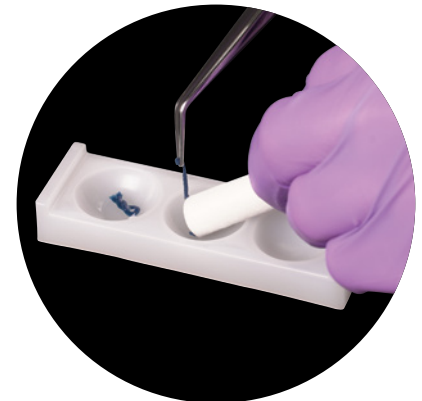


Fig. 22: Slightly dry the cord after removal from the retraction solution.

Mechanical retraction with non-impregnated cords alone seems to be less suitable for a successful tissue management as the cord removal can cause a hyperemic response and an increase of the sulcus fluid flow rate. Thus, when using a non-impregnated cord it is suggested to soak it with a suitable retraction solution (fig. 20 & 21). Cords that are already impregnated by the manufacturer must not be additionally soaked with a retraction solution due to possible interactions.



Hint: Mixing of different agents should be avoided due to possible unwanted effects. For example, mixing of epinephrine with ferric sulfate preparations leads to the appearance of a difficult to remove blue/black precipitate (fig. 23).



Fig. 23: In the left hollow: non-impregnated cord, soaked in ferric sulfate (no discoloration). In the central hollow: cord pre-impregnated with epinephrine, without additional soaking (pink). In the right hollow: Cord pre-impregnated with epinephrine, additionally soaked in ferric sulfate (blue/black discoloration due to the interaction).

09

Retraction cord techniques

Basically there are two different retraction cord techniques: the single cord technique and the double cord technique (fig. 24).

Single cord technique: one single retraction cord is placed into the gingival sulcus (fig. 25 & 26). After the appropriate length of stay (always follow the instructions of use) the cord is removed immediately prior to impression taking. The single cord technique is recommended when having a shallow sulcus or only a few prepared teeth.

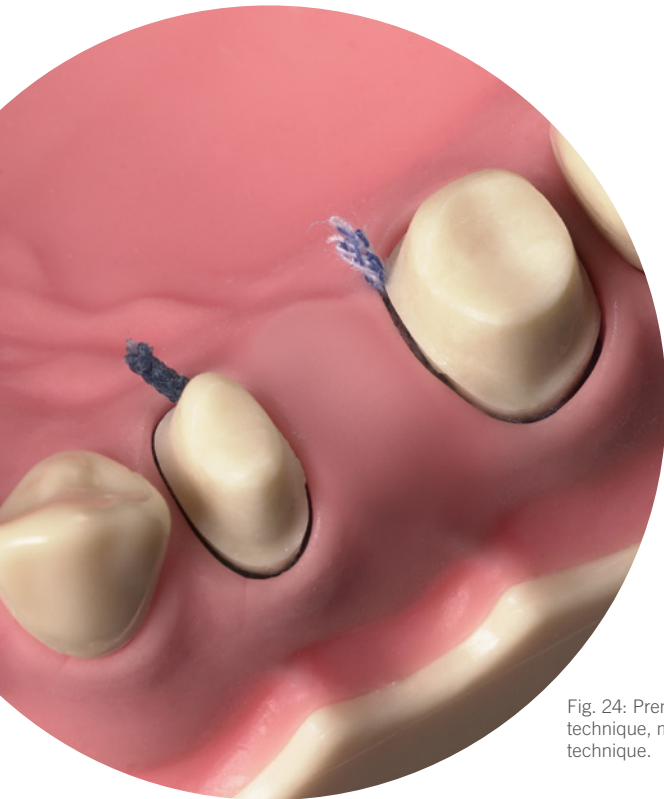


Fig. 24: Premolar with single cord technique, molar with double cord technique.

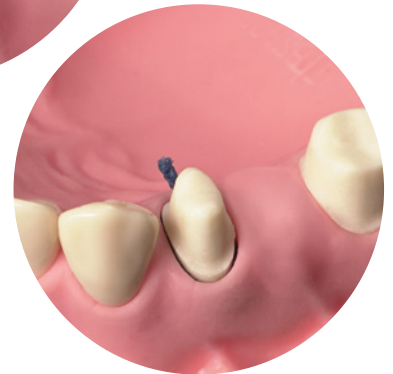
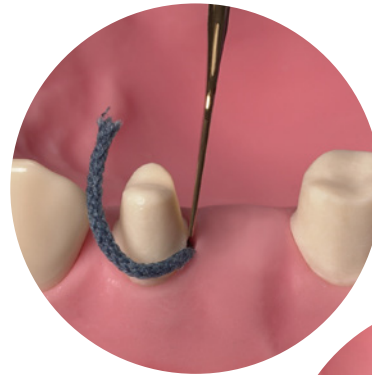
Fig. 25 & 26: Placement of the impregnated retraction cord for the single cord technique (above). Clearly visible preparation margin at the premolar after cord placement (below).



Double cord technique: First, a thinner cord is introduced into the sulcus slightly below the preparation margin; afterwards a second thicker cord is placed on top (fig. 27 & 28). Only the second cord is removed immediately prior to impression taking. That technique is especially recommended when having a deep sulcus or multiple prepared teeth.

The retraction cord should be sufficiently long without overlapping in the sulcus. If the cord is too short, the tissue between the cord endings will not be sufficiently displaced. For the cord removal the cord should not be completely dry as it can injure the tissue and induce bleeding once again. Immediately after successful impression taking, remaining cords have to be removed from the sulcus (double cord technique!). Any cords or residues of cords left behind in the sulcular area can cause massive inflammations.

Tip: Finishing of the preparation margin after placement of the first retraction cord in order to protect the marginal gingiva from a potential injury by rotating instruments (fig. 29).

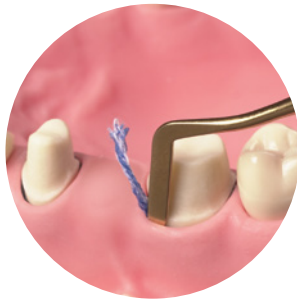
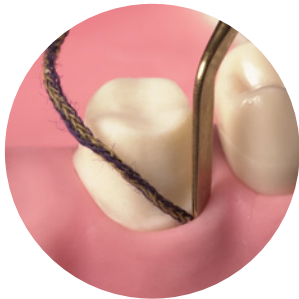

Fig. 27 & 28: Combination of a thinner first cord (left) with a second thicker cord for the double cord technique (right).

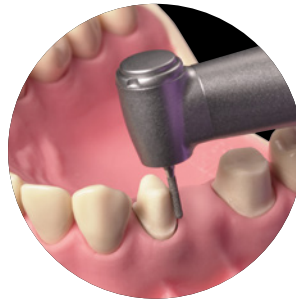

Fig. 29: Finishing of the preparation margin with a retraction cord in place.

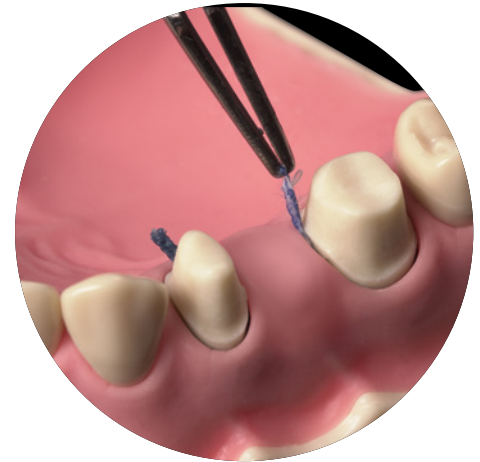


Fig. 30: A protruding cord end enables easy grasping with tweezers for the cord removal.



Tip: Ideally, a small part of the cord protrudes from the sulcus to facilitate grasping of the cord with the tweezers for a quick removal prior to the application of impression material (fig. 30). Positioning of the protruding cord end in a way that is easily accessible by the person that is supposed to grasp it.

10

Vasoconstrictors and astringents

As chemical components for local hemostasis during soft tissue management, vasoconstrictors or astringents are used. Usually they are combined with a mechanical component: chemo-mechanical retraction (fig. 31 & 32).

Vasosonstrictors, such as adrenaline (epinephrine), have a vasoconstrictive effect. However, it must be kept in mind that they also have a systemic effect and can influence the cardiovascular system.

The effect of astringent agents (e.g. ferrous sulfate, aluminum chloride) is based on their ability for precipitation of proteins. Ferrous salt compounds: By local precipitation of proteins in the blood, ferrous sulfate causes obstruction of the blood vessels. Aluminum salt compounds: The precipitation of proteins results in a slight tissue shrinkage and thus in the constriction of the capillary blood vessels in it.



Hint: Due to the systemic effect of epinephrine care should be taken with epinephrine-soaked retraction cords in risk patients, e.g. patients with cardiovascular diseases. Furthermore, the risk of overdosing due to cumulative effects of epinephrine containing retractions cords and epinephrine containing local anesthetics needs to be considered (dependent on e.g. the number of cords, duration of application, amount of local anesthetic injected). Alternatively, astringent agents that have no systemic effect can be used.




Fig. 31 & 32:
Soaking of a non-impregnated retraction cord for chemo-mechanical retraction.

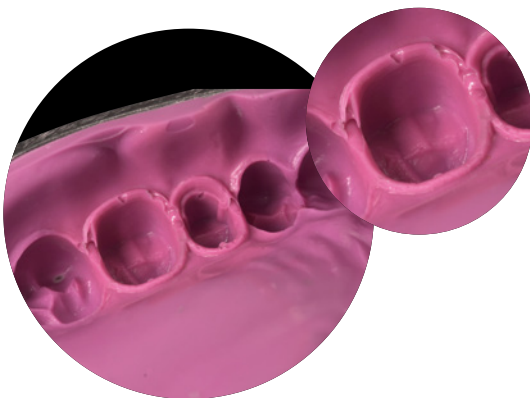

Fig. 33: Incorrect reproduction of the preparation margin due to chemical incompatibility between impression material and astringent.




Fig. 34: Placement of an impregnated cord on freshly mixed impression material in order to test the compatibility.



Fig. 35: Absence of an unpolymerized layer (smear layer) shows compatibility of the used materials.



Tip: Astringents can have an impact on the setting reaction of A-silicones (fig. 33). In case of unclarity (e.g. when changing the impression material or retraction aid) the compatibility should be tested beforehand (fig. 34). For this purpose, a piece of the respective cord is placed on freshly mixed impression material. Once the impression material is set, the cord is removed and the contact area of the two materials is inspected: absence of an unpolymerized layer (smear layer) shows compatibility of the two materials (fig. 35).

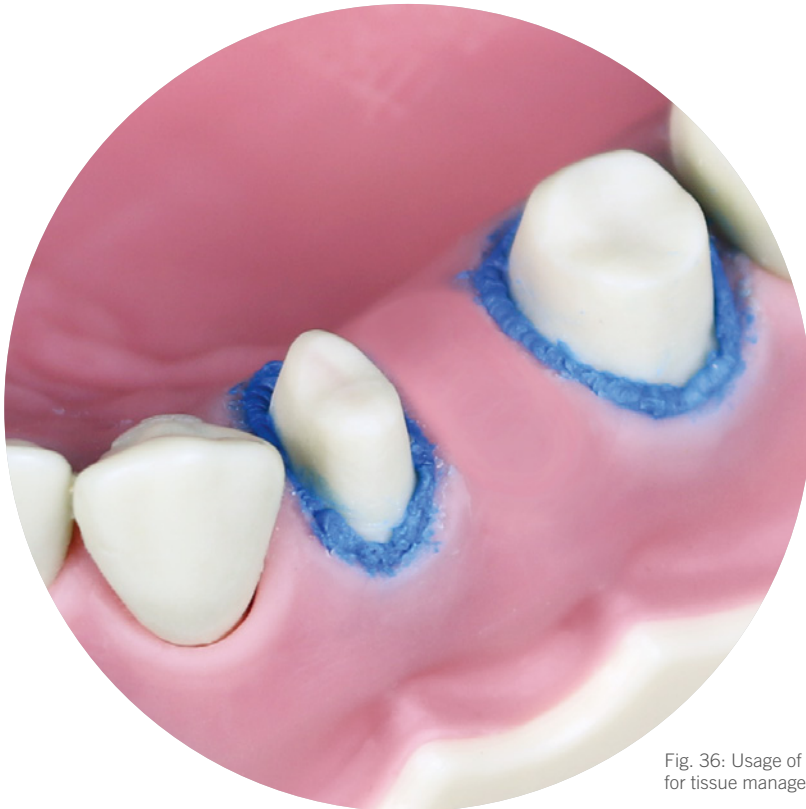


Hint: Astringents have a very low pH-value, so that a prolonged application time in the sulcus can cause chemical burns of the soft tissue. Hence, the recommended application times in the respective instructions for use have to be strictly followed.

11

Retraction pastes and gels

As an alternative to retraction cords, various pastes and gels for soft tissue management are available (fig. 36). Retraction pastes and gels usually contain an astringent component (often aluminum chloride 15%) which is responsible for the hemostatic effect, and a component for the tissue displacement (often kaolin, that absorbs sulcus fluid and expands). Usually the pastes are introduced into the sulcus with a blunt cannula and rinsed out after a certain application time. It very much depends on the clinical situation if such a procedure is suitable to replace the retraction cord.



Hint: Prior to the first usage it is recommended to check the compatibility of retraction pastes or gels with the impression material used in the dental practice.



Hint: You can find everything you need to know about retraction in our Tips & Tricks brochure “Soft Tissue Management”.



kulzer.com/retraxil-tipsandtricks

Fig. 36: Usage of a retraction paste for tissue management.

Tray adhesive

During the removal of the tray from the mouth the impression is subjected to enormous stresses, especially when the jaw exhibits strong undercuts. If the impression material has detached from the impression tray at one point, the impression is unusable. To ensure optimal adhesion of the impression material to the tray an appropriate tray adhesive should be used. To avoid stains on the practice furniture, the worktop can be covered with cellulose cloth that is fixed with adhesive crepe tape.

Ideally, the adhesive is applied in a thin layer shortly before impression taking (fig. 37 & 38), whereby it is necessary to observe the drying time declared by the manufacturer (fig. 39). The adhesive can only achieve optimal adhesion when the solvent is completely evaporated.



Hint: Each impression material (e.g. alginate, silicone, polyether) needs its special adhesive. Optimal adhesion can only be achieved by using an adhesive that is suitable for the respective impression material.

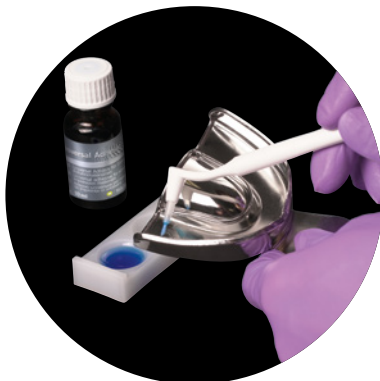


Fig. 37: Application of tray adhesive in a thin layer with a disposable brush.

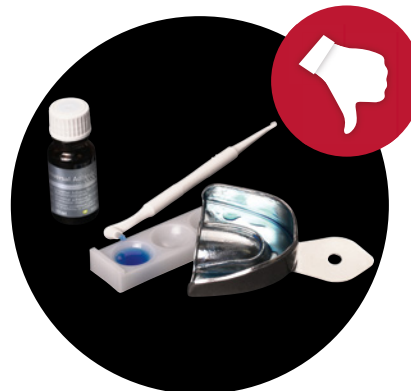

Fig. 38: Puddles of adhesive in the tray must be avoided.

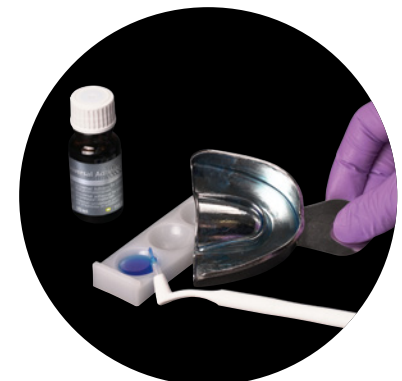


Fig. 39: After application, the adhesive is let to dry according to the instructions for use.



Tip: Residues of the silicone tray adhesive Universal Adhesive (Kulzer) can be removed from the tray with ethyl alcohol.

13

Double-mix technique

For the double-mix technique (single-stage, two-phase technique), the impression tray is filled with a highly viscous impression material (tray material) and the teeth are syringed with a medium or low viscosity material (wash material) (fig. 40).

When using a highly viscous tray material (heavy tray) it is recommended to use an individual tray made of rigid autopolymer. A stock tray can also be used alternatively. In any case, there should be a minimal distance of at least 3mm between tray wall and jaw/teeth, respectively a distance twice as big as the extent of the undercut. When using an individual tray at least some pressure can be exerted due to the defined uniform distance between the tray and the jaw. When using a stock tray that is not possible to that extend due to the uneven distance to the jaw.



Tip: To allow optimal adaptation of the impression material and to minimize the risk of flow defects, insert the tray into the mouth slowly.



Hint: A- and C-silicones should not be combined in the same impression, as they are two different types of silicones that do not achieve sufficient adhesion between each other.

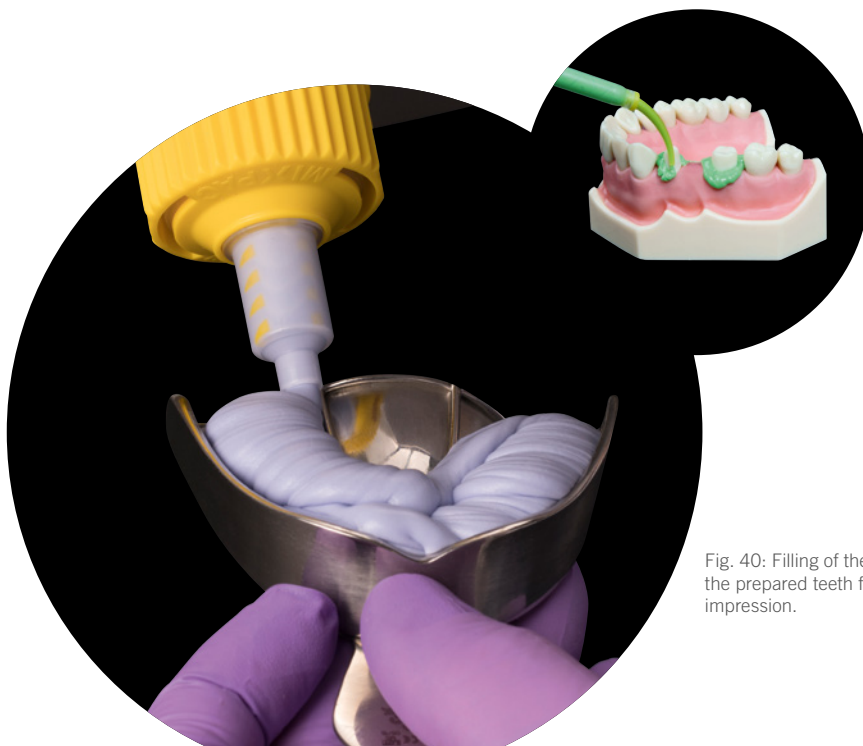


Fig. 40: Filling of the tray and syringing the prepared teeth for the double-mix impression.

The procedure of a single-stage, two-phase impression depends on the number of prepared teeth. In case of only one single prepared tooth, the dental assistant begins by filling the tray. Once the tray is half full, the dentist syringes around the prepared tooth in the mouth.

In case of more than two prepared teeth, dental assistant and dentist start at the same time as they both need the material's complete working time for syringing all prepared teeth and filling the tray.



Hint: When using an individual tray, the removal of the impression might be difficult due to the high shore A hardness of a heavy tray material in combination with a good flowing behavior, especially when having large undercuts of the jaw. In these cases, the distance has to be greater than 3 mm (fig. 42).

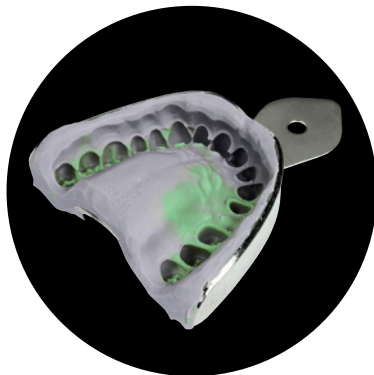


Fig. 41: Finished flawless double-mix impression.



Fig. 42: Ensure that sufficient distance is present between tray wall and teeth/jaw.

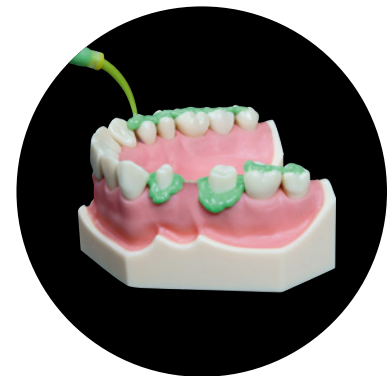

Fig. 43: Application of wash material onto the occlusal surfaces to avoid air voids in that area.



Tip: Application of wash material onto the occlusal surfaces of the unprepared teeth (fig. 43) to avoid air bubbles in the area of the occlusal surfaces.

14

Sandwich technique

For the sandwich technique (single-stage, two-phase technique) usually a kneadable impression material (putty) is used as a tray material. When using a kneadable impression material a stock tray is recommended. Furthermore, the wash material should not be too low viscous. A too low viscous wash material might be too strongly displaced by the kneadable tray material, thus causing steps in the impression in the area of the vertical tooth surfaces. The wash material is applied in a not too thin layer onto the tray material (fig. 44). The positive effect of the additional material reservoir becomes especially apparent in clinical situations with large undercuts. In these cases, the viscoplastic putty material is not able to sufficiently reach the undercuts, but it pushes the medium viscous material (available in sufficient quantities) into the undercuts which it cannot reach itself.



Tip: To allow optimal adaptation of the impression material and minimize the risk of flow defects, insert the tray into the mouth slowly (fig. 45).

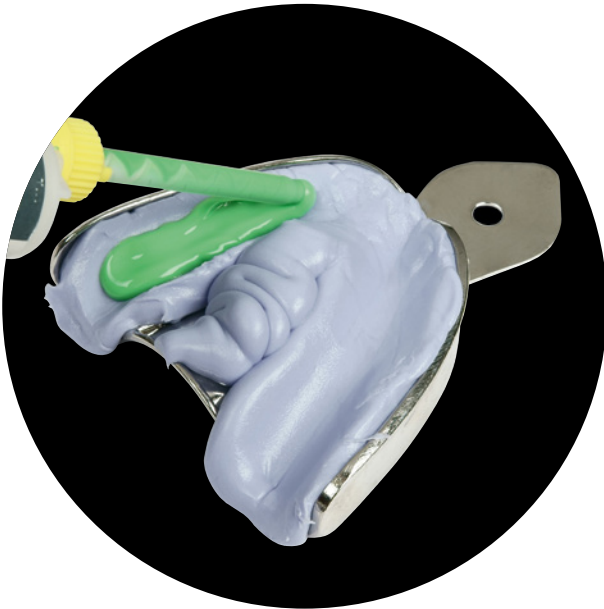

Fig. 44: Application of wash material onto the tray material.




Fig. 45: Finished flawless sandwich impression with Flexitime Putty and Flexitime Medium Flow.

Monophase technique

The monophase technique is a single-stage, one-phase impression technique. One impression material, usually of medium viscosity, is used for filling the tray and for syringing the prepared teeth (fig. 46). Usage of an individual tray is recommended, to achieve a uniform material thickness and at least some pressure.

The monophase technique is a relatively easy and quick impression technique. It is particularly suitable when having supragingival preparations or for transfer- and implant impressions. Concerning transfer-/implant impressions, care should be taken that the shore A hardness of the impression material is sufficiently high to ensure a secure fixation of the primary parts/implant posts in the impression.

Advantage over the single stage, two-phase techniques is that only one single consistency of the impression material is used. Thus, displacement effects due to usage of different consistencies can be eliminated.



Tip: Application of wash material onto the occlusal surfaces of the unprepared teeth (fig. 47) to avoid air bubbles in the area of the occlusal surfaces (fig. 48).

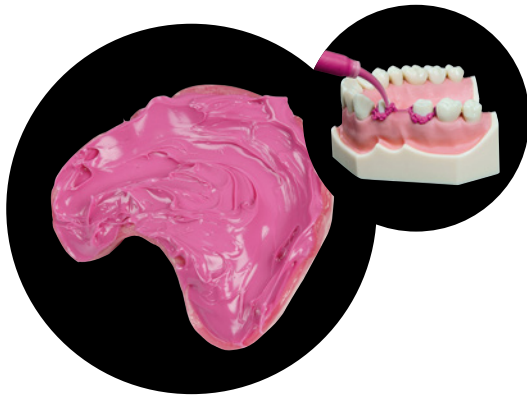

Fig. 46: For the monophase technique, a medium viscous material is used for filling the tray as well as for syringing the teeth.

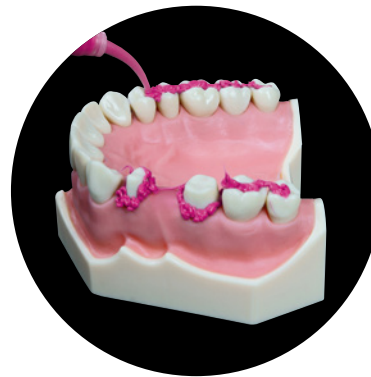

Fig. 47: Application of wash material onto the occlusal surfaces to avoid air voids in that area.

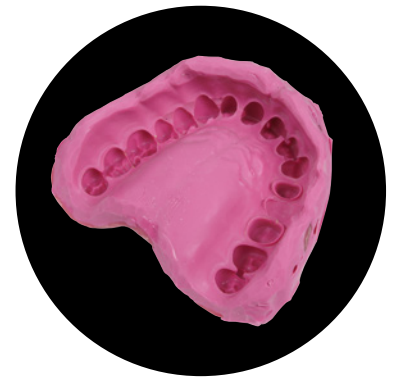

Fig. 48: Finished flawless monophase impression with Flexitime Monophase.

16

Patient positioning and tray insertion

In general, the dentist is standing up and the patient is sitting upright during impression taking. For taking an impression of the upper jaw, it is also possible to initially position the patient in a slightly backwards inclined position and bring him in the upright position after the insertion of the tray.

When taking an impression in the upper jaw, the dentist can stand slightly behind the patient. For the insertion of the tray one corner of the mouth is kept away with the finger and the other side is displaced with the slightly inclined tray (fig. 50). Afterwards the tray is aligned straight and pushed into position from the back to the front in order to prevent excess material from flowing into the patient's throat (fig. 51). Afterwards the tray is kept in place by the dentist without exerting further pressure or movement until the end of the intraoral setting time (fig. 52).

Alternatively, the dentist initially stands in front beside the patient for the insertion of the tray, and then steps behind the patient to push the correctly aligned tray into position.



Hint: During impression taking the patient should not be lying flat (fig. 49).

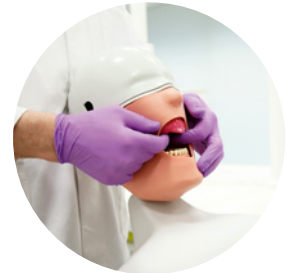

Fig. 51: The straightly aligned tray is pushed into its final position.

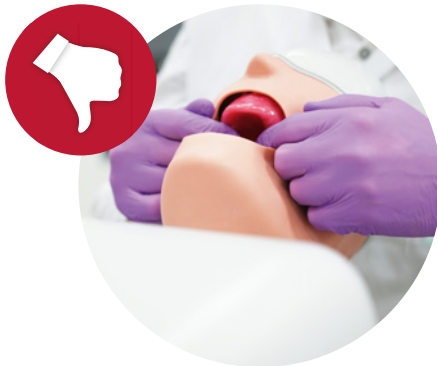

Fig. 49: Incorrect positioning of the patient during impression taking.

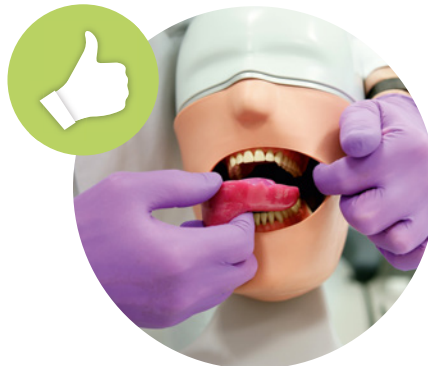

Fig. 50: One corner of the mouth is kept away with the finger, the other side is displaced with the impression tray.

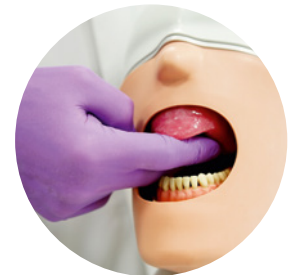

Fig. 52: The impression is kept in place without exerting further pressure.

For impressions of the lower jaw, the dentist is standing in front beside the sitting patient. The tray is inserted slightly inclined to displace one corner of the mouth with the tray. The other corner of the mouth is kept away with the finger so that the tray can slid past him (fig. 53). Afterwards the tray is aligned straight and pushed into position from the back to the front. The tray is then kept in place by the dentist without exerting further pressure or movement until the end of the intraoral setting time (fig. 54).

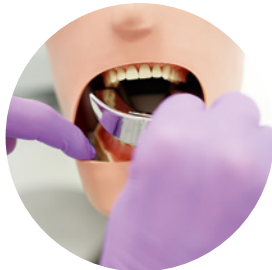

Fig. 53: One corner of the mouth is kept away with the finger, the other side is displaced with the impression tray.

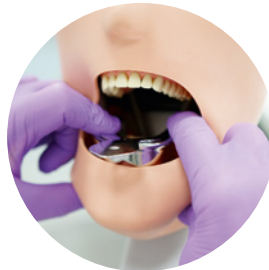

Fig. 54: The tray is slowly pushed into position from the back to the front and then is kept in place without further pressure.

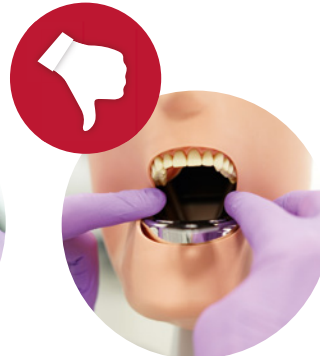

Fig. 55: When keeping the impression in place, care must be taken that the patient's cheek is not accidentally pinched.



Hints: The jaw should be positioned centrally in the tray to achieve a uniform layer of impression material (minimum 3 mm).

Always take care not to trap the cheek of the patient accidentally between the fingers and the tray (fig. 55).

Once the tray is correctly place in the mouth the dentist keeps the tray in position without exerting further pressure or movement until the end of the intraoral setting time (fig. 52).



Tip: Do not advise the patient “to open his mouth wide”, as this tempts him to open his mouth as wide as possible. Due to this the cheeks' soft tissue is under maximal tension and impedes the tray insertion. In addition, the ascending lower jaw branch can interfere in the dorsal area of the upper jaw. Thus, the patient should not open his mouth maximally, but lips and cheeks should still be relaxed.

17

Working time and intraoral setting time

The working time starts with mixing of the materials (base & catalyst) and includes filling of the tray, syringing the teeth and inserting the tray into the mouth.

The intraoral setting time starts with the end of the working time. Instructions for use often specify the minimum time in mouth, i. e. the earliest possible point in time to remove the impression from the mouth. However, in practice it needs to be considered that the specified intraoral setting time is measured from the end of the specified working time. In other words, in such cases where the tray is inserted before the end of the specified working time (e. g. single-tooth impression), the intraoral setting time needs to be extended accordingly. Otherwise, the impression material is not yet fully cured at removal. In general, a watch or a material sample at room temperature can help to control the (extraoral) working time.



Hint: The intraoral setting time specified in the instructions for use is measured from the end of the specified working time.

Innovative time concept		
	Flexible working time	Short intraoral setting time
Flexitime multiple-unit impression	2:30	2:30
Flexitime single-tooth impression	1:00	2:30

The A-silicone Flexitime offers an intelligent time-concept. Due to its special formula, Flexitime controls the polymerization kinetics by mouth temperature. In other words, Flexitime combines a flexible working time varying from 1:00 to 2:30 min with an always short intraoral setting time of 2:30 min. Thus, more leeway is given and the necessity for an extension of the time in mouth is reduced.

Removal of the impression

After the setting of the impression material, the impression is removed from the mouth. For the removal the index finger is placed vestibularly on the rim of the tray on each side and pressure is exerted slowly (fig. 56). The thumbs are located underneath the tray between upper and lower jaw in order to protect the teeth of the opposing jaw in case the tray suddenly releases (fig. 57).

If possible, the impression is removed in the axial direction from the prepared tooth/teeth, so that the impression in the area of the prepared teeth experiences the least deformation. As the posterior teeth in the upper jaw are inclined to the buccal, the impression should be first released on the side with the unprepared teeth. In the lower jaw where the teeth are inclined to the lingual, the impression is first released on the side with the prepared teeth. Concerning the front teeth: the impression is first released from the dorsal vestibulum and then tilted towards the front teeth, enabling a tray removal parallel to the axes of the prepared teeth.

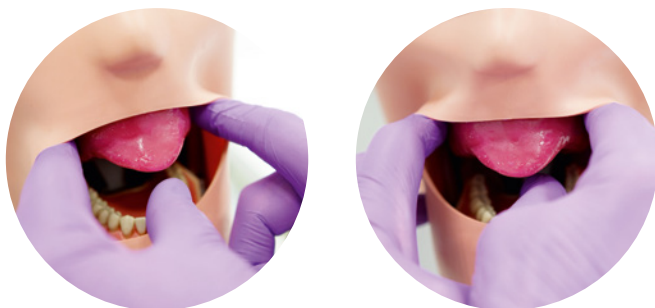

Fig. 56 & 57: Release of the impression tray from vestibular. The thumb serves as protection for the teeth of the opposing jaw.



Hint: If strong undercuts of the jaw impede a quick release of the tray, do not simply pull at the tray handle. Instead, alternately exert pressure with the index fingers on the vestibular impression tray rim until the impression releases (fig. 58).

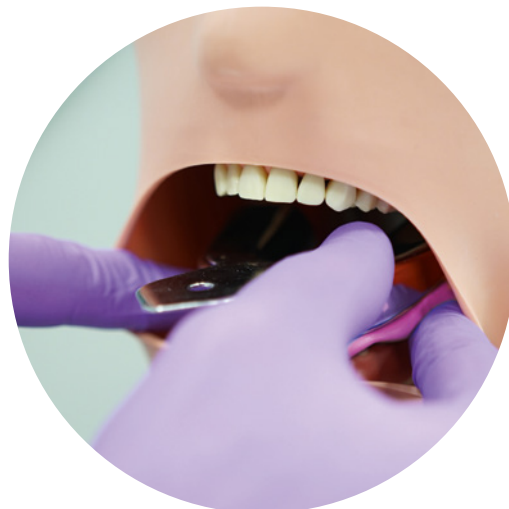

Fig. 58: Do not simply pull at the tray handle, but alternately exert pressure on the tray rim from vestibular until the impression releases.

19

Assessment of the impression

After the removal from the mouth, the impression is cleaned under running water from blood and saliva and dried with the air syringe (fig. 59). Now the quality can be evaluated:

- All teeth of the jaw need to be entirely captured in the impression material and need to be completely located in the impression tray. Particular attention should be paid to the terminal teeth (exceptions could be teeth without antagonist contact or missing antagonist teeth).
- The tray should be placed centrally to the jaw midline to ensure a uniform distance between jaw and tray wall (3 mm minimum impression material layer thickness).
- The tray should not be pushed against the occlusal/incisal edges, i.e. the tray bottom should not be visible in the impression. By direct pressure of the rigid tray on the teeth, the teeth can be pushed into the socket and thus get recorded in a physiologically incorrect position. Incisal/occlusal inaccuracies of the restoration can be the consequence.

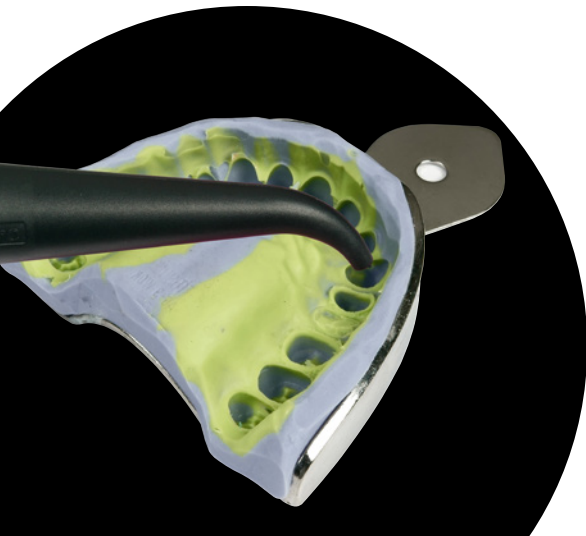

Fig. 59: Drying of the impression to assess the quality.

20

Cleaning and disinfecting the impression

Immediately after the removal from the mouth, the impression is thoroughly rinsed under running water. Prior to the transfer to the lab, the impression has to be disinfected by using specifically suitable disinfectants. Other disinfectants, such as surface disinfectants, can not only damage the impression material but also the model plaster. In addition, it needs to be ensured that the disinfectant is suitable for the used class of impression material.

To ensure that all areas of the impression are reached during immersion disinfection, a complete wetting of the impression is necessary (fig. 60 – 62). The exposure time specified in the instructions for use has to be strictly followed. Once the exposure time has elapsed, the impression is thoroughly rinsed under running water (fig. 63) and dried afterwards. Ideally, the number of impressions that is disinfected in the immersion bath is recorded to ensure a timely exchange of the solution and thus the efficacy of the disinfection solution.

The information about impression disinfection in the dental practice should be given to the dental lab. Otherwise, the lab has to assume that the impression is not disinfected and needs to take appropriate measures.



Hint: The disinfection solution needs to be rinsed off thoroughly, as residues of the disinfection solution can damage the model plaster.



Tip: Air bubbles at the impression that impair the complete wetting, can be avoided by repeatedly dipping the impression briefly into the disinfection solution.

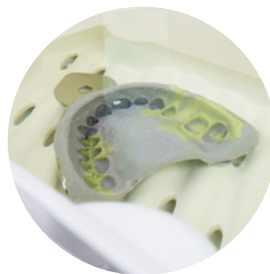

Fig. 60 – 62: To avoid air bubbles at the impression, briefly dip the impression repeatedly into the disinfection solution before leaving it in the disinfection solution for the exposure time specified in the instructions for use.

Fig. 63: Thorough rinsing of the impression after the disinfection bath.

21

Storage and transport of the impression

A-silicone impressions have no special requirements concerning storage and transport, as A-silicones possess a high dimensional stability. However, for best results the following hints for storage and transport should be considered:

Ideally, only the tray touches the transport box. Special transport containers allow a suspended fixation of the impression trays. Otherwise, the transport box needs to be upholstered to avoid damage of the impression due to sliding around.

Dry conditions should be ensured during storage and transport of silicone impressions. Temperatures above 25 °C are to be avoided.

22

Opposing arch impression, bite registration and provisional

In addition to the precision impression, an impression of the opposing jaw and a bite registration are necessary for the fabrication of the indirect restoration. Usually, alginate or alginate substitute impression materials are sufficient for the situation impression of the opposing jaw. For the bite registration (fig. 64) specially suitable A-silicones with an extra-high final hardness are available.

For the period until the insertion of the definitive restoration, a temporary restoration needs to be fabricated. Further information concerning the fabrication of the provisional can be found in the tips and tricks guide “Direct fabrication of provisionals” by Kulzer (fig. 65).

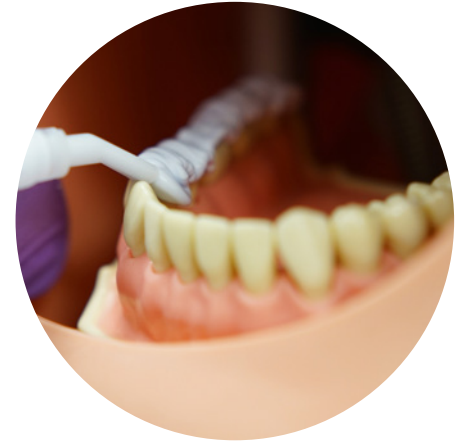

Fig. 64: Application of Flexitime Bite with a specially suited wide tip (bite registration tip).

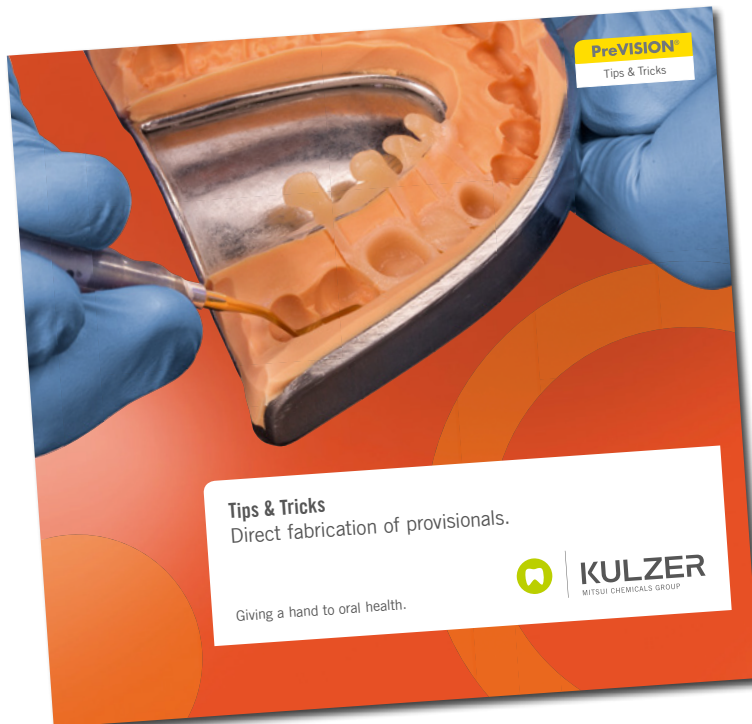

Fig. 65: Tips & Tricks brochure “Direct fabrication of provisionals”.



kulzer.com/prevision-tips-tricks

