

RetraXil®

Tips & Tricks

Tips & Tricks Soft Tissue Management

Giving a hand to oral health.



KULZER
MITSUI CHEMICALS GROUP

Content

01

General information on soft tissue management

p. 06

- 1.1 The perfect time for the impression p. 06
- 1.2 Bleeding and hemostasis p. 08

02

Soft tissue management techniques

p. 11

- 2.1 Surgical retraction techniques p. 11
- 2.2 Chemical retraction techniques p. 12
 - 2.2.1 Medicinal additives to support haemostasis p. 12
- 2.3 Mechanical retraction techniques p. 14
 - 2.3.1 Retraction cords (non-impregnated) p. 14
- 2.4 Chemical/mechanical retraction techniques p. 15
 - 2.4.1 Retraction cords (impregnated/soaked) p. 15
 - 2.4.2 Pastes p. 16

03

RetraXil

p. 17

- 3.1 Use of RetraXil in different indications p. 18
 - 3.1.1 Analogue impression p. 18
 - 3.1.2 Digital impression p. 22
 - 3.1.3 Before cementing temporary and definitive restorations p. 24
 - 3.1.4 Before placing Class V/II fillings p. 26
 - 3.1.5 In combination with retraction cords p. 29

04

Cleaning and disinfection p. 32

- 4.1 Cleaning and disinfection of the twisting aid p. 33
- 4.1.1 Cleaning and disinfection by hand p. 33
- 4.1.2 Cleaning and disinfection: Automated disinfection p. 34

05

Sterilisation p. 35

06

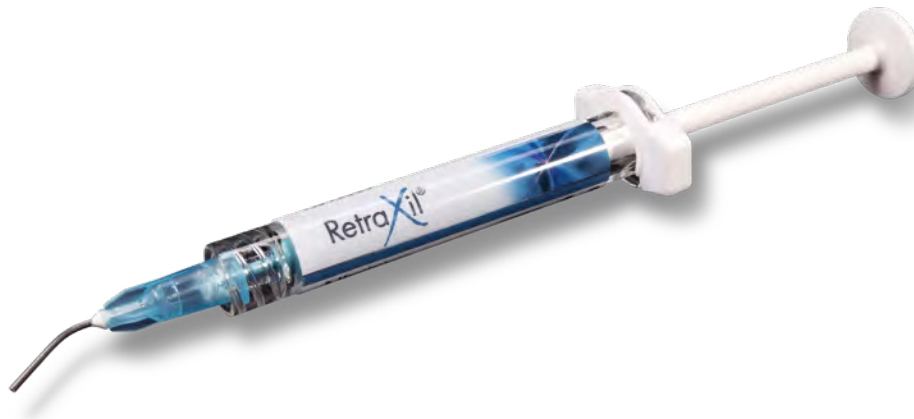Sources p. 37

Preface

A precise impression is the basic prerequisite for a precisely fitting prosthetic restoration. This not only depends on the selection of a suitable impression technique and material, but also on adequate soft tissue management.¹ The aim is to always achieve an accurate impression of the preparation and ultimately to ensure the preservation of the abutment tooth and its gingival and periodontal health.²

In everyday clinical practice, an equi- or subgingival preparation is often unavoidable. This presents the practitioner with two main challenges. On the one hand, the sulcus must be kept temporarily open by suitable measures, so that the impression material can flow to the areas to be captured.^{3, 4} On the other hand, adequate isolation and presentation of the preparation margin is essential, even though modern impression materials have a high degree of hydrophilicity and flowability.⁵

This also applies to digital impressions: If saliva and bleeding are not brought under control and if the sulcus is not sufficiently opened, the preparation margin cannot be sufficiently captured. In addition, the reflections emitted by blood and saliva interfere with the optical detection of the preparation.⁶



When cementing permanent and temporary restorations, it is also often necessary to ensure adequate soft tissue management so as to keep the sulcus temporarily open and to stop bleeding in order to ensure that the luting cement sets. The same basic requirements apply to the placement of certain restorative materials. On the one hand, adhesive luting systems require for the cavity to be completely dry. On the other hand, appropriate retraction measures prevent the filling materials from becoming permanently discoloured due to blood residue.

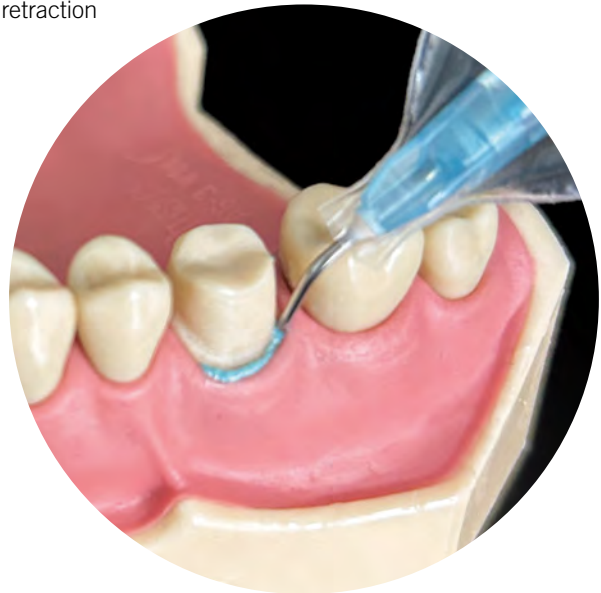In order to ensure that the sulcus is kept open and dry, various retraction techniques are available.

The retraction paste RetraXil (Kulzer) combines through its composition the advantages of mechanical and chemical retraction such as non-invasiveness, ease-of-use, effectiveness, time-saving and patient comfort.

With this Tips & Tricks Guide, we hope to provide you with the most information on the subject of soft tissue management and retraction.



Dr. med. dent. Annika Herr
Global Scientific Affairs Manager
Hanau (Germany)



01

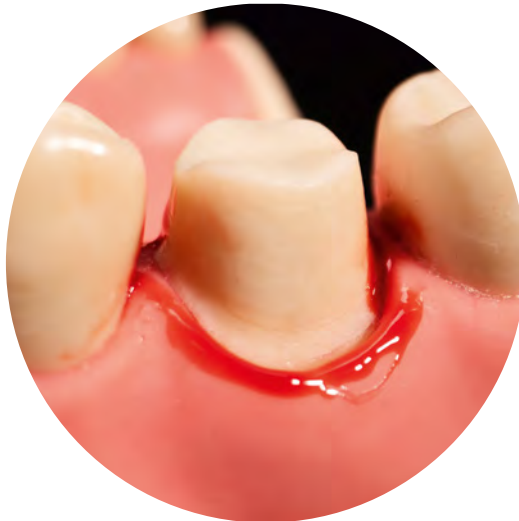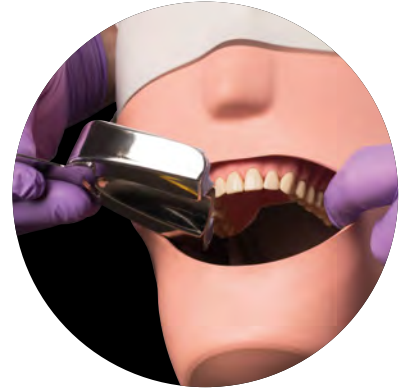General information on soft tissue management

1.1 The perfect time for the impression

In everyday practice, the question often arises as to when is the perfect time to take an impression after preparation.

As a rule, the preparation process causes the surrounding soft tissue to be injured by the dental drills. Directly after the trauma, the granulation tissue is highly vascularised, which can make it difficult to stop the bleeding that occurs.⁷

Approximately one week after the preparation, the tissue has usually healed and a successful impression is possible with the use of appropriate retraction techniques.⁸

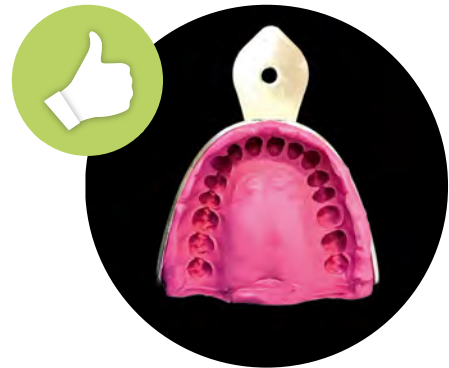

Bleeding after preparation

However, impressions can also be taken directly after preparation, if the preparation margin is supragingival or if subgingival areas can be reliably kept dry.⁹



Exact representation of the preparation margin with Flexitime Monophase.



Finished flawless Monophase impression with Flexitime Monophase.



Hint: Patients with gingivitis or periodontitis have an increased tendency to bleed due to the inflammatory parameters. Affected patients must be treated accordingly before planning a prosthetic restoration.¹⁰

Hint: Tissue that was injured during preparation heals in the first phase by forming granulation tissue. This granulation tissue has a strong blood supply and is unstable due to the formation of new vessels. Impressions taken in this phase are often not promising.⁷


1.2 Bleeding and hemostasis

When a tooth is prepared equi- or subgingivally, trauma to the marginal gingiva is inevitably caused by the dental drills.¹ But gingivitis (inflammation of the gums) can also trigger bleeding after preparation, as can cord placement and removal of the cord from the sulcus.^{10,12}

Physiological blood coagulation describes the process from a liquid state of the blood to a gel-like state to a solid thrombus. In principle, there are three reaction pathways how clotting is accomplished: The vascular reaction (the injured vessel tries to reduce blood loss by contraction of the smooth muscle cells), the thrombocyte activation (closure by accumulation of thrombocytes = blood platelets) and by contact with foreign surfaces.¹¹



Hint: Even though modern impression materials have a high degree of hydrophilicity and flowability, in case of bleeding and leakage of sulcus fluid, isolation is absolutely necessary to ensure that the impression material flows and to prevent imperfections in the impression.¹³



Incorrect representation of the preparation margin due to insufficient haemostasis before taking the impression.



Hint: If such an underlying disease or drug therapy exists (e.g. with Heparin or Marcumar), the attending dentist must take preparatory measures in consultation with the attending general practitioner before treatment. The query of illnesses/medication intake is carried out by means of the anamnesis form and in the explanatory consultation.

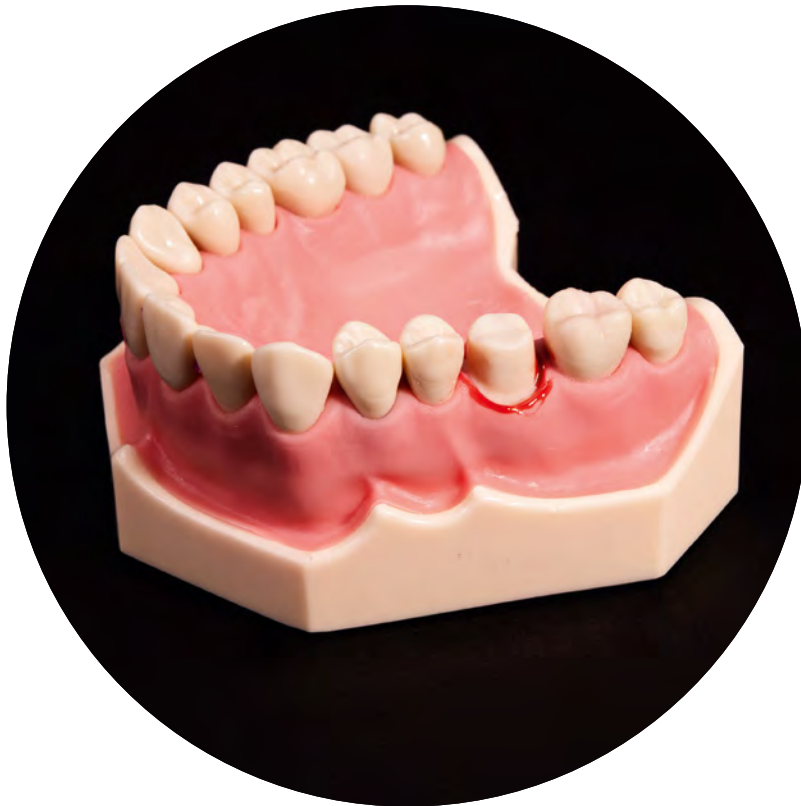In certain clinical pictures, blood coagulation is disturbed. These include congenital plasma factor deficiency diseases such as haemophilia A, haemophilia B, von Willebrand-Jürgens-disease, as well as acquired plasma factor deficiency diseases such as chronic liver diseases, immunocoagulopathies, thrombocytopenias, thrombocytopathies and thrombocytopenias. Bleeding disorders such as thrombocytopenias, thrombocytopathies (e.g. platelet aggregation inhibition) and vascular bleeding disorders (congenital bleeding disorders (congenital vasopathies [e.g. capillary fragility] and acquired vasopathies) [e.g. defective collagen formation]).^{14,15}

Clinical picture	Cause
Haemophilia A	Factor VIII deficiency
Haemophilia B	Factor IX deficiency
Willebrand-Jürgens-disease	Reduced efficacy of factor VIII carrier protein, resulting in inadequate adhesion of platelets to the endothelium
Thrombocytopenia	Decreased number of platelets

Coagulation disorders and affected coagulation factors

Likewise, various therapeutic agents can lead to an increase in the bleeding tendency of the corresponding patients. For example, coumarin therapy (vitamin K antagonists such as Marcumar), heparin therapy, taking acetylsalicylic acid, as well as therapies with new oral anticoagulants (= DOAK: Direct Oral Anticoagulants, which act by directly inhibiting blood clotting factors).^{14,15}

Postoperative haemorrhages without underlying disease are also possible and occur in dental practice, for example, when the vasoconstriction of the vessels decreases due to the degradation of the local anaesthetic. In addition consumption of alcohol (intensification of vascular dilatation) or coffee (increase in blood pressure due to caffeine) before or after treatment can lead to increased post-treatment bleeding. Wound healing disorders can also contribute to bleeding after dental treatment.¹⁵



Bleeding after preparation of a maxillary molar.

Soft tissue management techniques

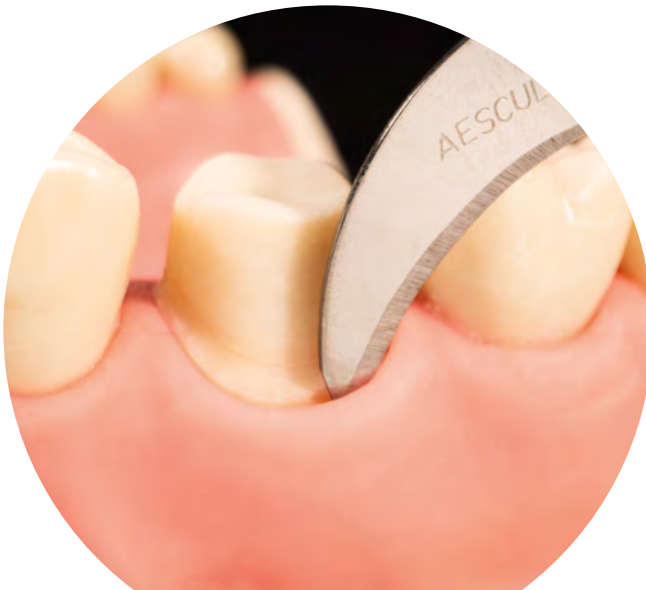To achieve haemostasis as well as sufficient temporary opening of the sulcus, surgical, chemical and mechanical techniques can be used, as well as a combination of the different options.

2.1 Surgical retraction techniques

If surgical methods are used, the soft tissue is irreversibly removed. This can be done with a scalpel, an electrotome or a laser. The advantage of electrosurgery/laser surgery is that cutting and haemostasis are done in one step. However, if the electrotome comes into contact with the tooth structure, root cementum can be destroyed and root resorption can occur as a result. The heat generated can also permanently damage tissue, resulting in recession and loss of attachment as well as wound healing problems. As a result, tooth sensitivity can also occur.^{1,17}



Hint: Surgical techniques always cause irreversible soft tissue loss. Therefore, they should only be used if other retraction techniques fail.¹



Intrasulcular incision by means of a scalpel.

2.2 Chemical retraction techniques

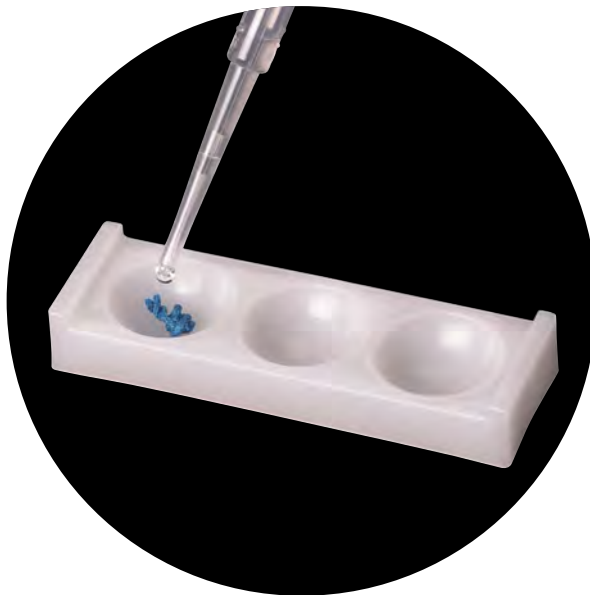
2.2.1 Medicinal additives to support haemostasis

With regard to haemostasis after preparation and before impression taking, the following groups of medicinal additives are distinguished in dentistry: Vasoconstrictors and astringents.

Vasoconstrictors such as adrenalin cause contraction of the smooth muscles of the vessels. The sympathomimetic adrenaline has a vasoconstrictor effect when applied locally. Locally injected adrenaline can, however, depending on the type of application, be flushed into the systemic circulation and also have an effect there (which is not desired here).¹⁷



Hint: The sympathomimetic adrenaline can cause the following possible systemic effects: Tachycardia (exceeding the normal physiological heart rate for the age of the patient), tachypnoea (increased breathing rate), increase in blood pressure, anxiety, shakiness, postoperative depression.¹



Soaking of a non-impregnated cord with a medicinal additive.

Astringents, such as aluminium compounds, cause tissue shrinkage by precipitating proteins and thus cause constriction of the capillaries running in them. Aluminium chloride, aluminium sulphate and alum (aluminium potassium sulphate) are aluminium compounds that are often used for local haemostasis. No systemic side effects are known for aluminium compounds.

Ferrous sulphate also has a haemostatic effect. When ferrous sulphate comes into contact with blood, small coagulums form which close the capillaries and thus stop the bleeding. Systemic side effects are also not known with the use of ferrous sulphate.¹⁸



Hint: Ferrous sulphate may temporarily discolour the tissue to a brownish colour. Never use together with adrenalin: Massive blue-black discolouration of the tissue may result.¹⁷



In the left well: Non-impregnated cord, soaked in ferrous sulphate (no discolouration).

In the middle well: Cord pre-impregnated with adrenalin, without additional impregnation (pink).

In the right-hand well: Cord pre-impregnated with adrenalin, additionally soaked in ferrous sulphate (blue-black discolouration of the thread due to the interaction).



Hint: Astringents can prevent the setting reaction of polyethers and addition-curing silicones and must therefore be rinsed thoroughly before taking the impression.⁶

2.3 Mechanical retraction techniques

2.3.1 Retraction cords (non-impregnated)

Retraction cords are usually cotton cords that absorb liquids. They are available in different diameters and different types, i.e. twisted, braided or circular knitted. A distinction is also made between the untreated (non-impregnated) and the impregnated versions. Untreated cords cause a purely mechanical retraction. If the soft tissue is to be displaced by a cords, this can be done using the so-called single-cord technique or the double-cord technique.



Hint: Purely mechanical retraction with unimpregnated cords may lead to reactive hyperaemia (increased blood flow) and increased sulcus flow rate after removal of the cord. Therefore, when using untreated cords, it is recommended to soak them with a suitable retraction solution before use.¹³



Hint: Cord placement causes trauma that requires approximately 10 days of healing and may leave recessions of 0.2mm. Furthermore, cords left behind or remnants of cords can cause massive inflammation!²⁰



**Flexitime Tips & Tricks Guide
One-Step Impression Technique**



**Flexitime Tips & Tricks Guide
Two-Step Impression Technique**

You can find more information on the individual cord techniques in the Kulzer Flexitime Tips & Tricks Guides.

You can find more information on the individual thread techniques in the Kulzer Flexitime Tips & Tricks Guides.

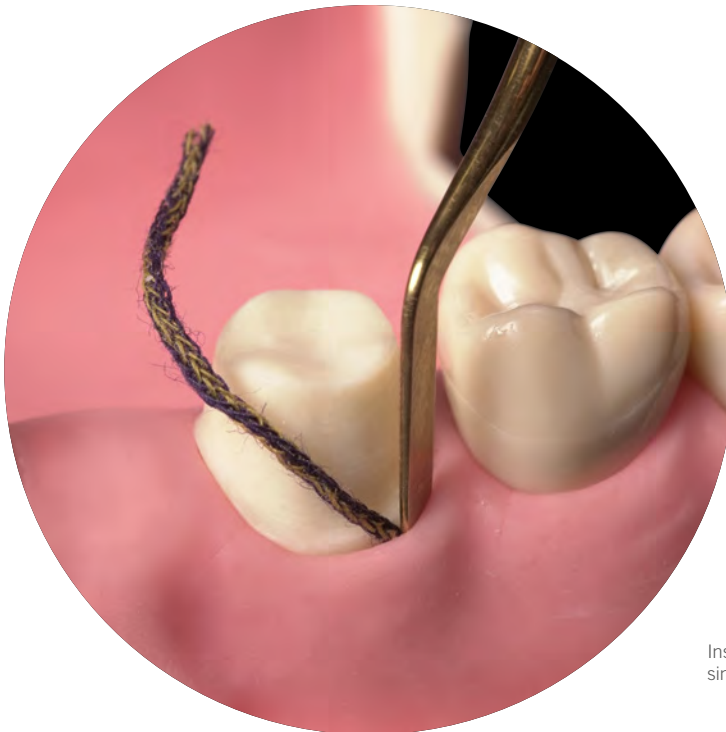
2.4 Chemical/mechanical retraction techniques

2.4.1 Retraction cords (impregnated/soaked)

Impregnated cords are already provided by the manufacturer with a chemical component to stop bleeding. Since the active ingredient is contained in the impregnated cord in dried form, a sufficient amount of sulcus fluid is necessary to dissolve it. Cords without active ingredient can be impregnated with a retraction solution intended for this purpose and achieve a haemostatic effect through the medicinal additive.¹⁹



Hint: There is a risk of overdose! Possible cumulative effects must always be taken into account (additional local anaesthesia, number of teeth prepared, number of impressions, further medication, stress, cardiovascular condition of the patient, etc.).¹



Insertion of a retraction cord with the single cord technique.

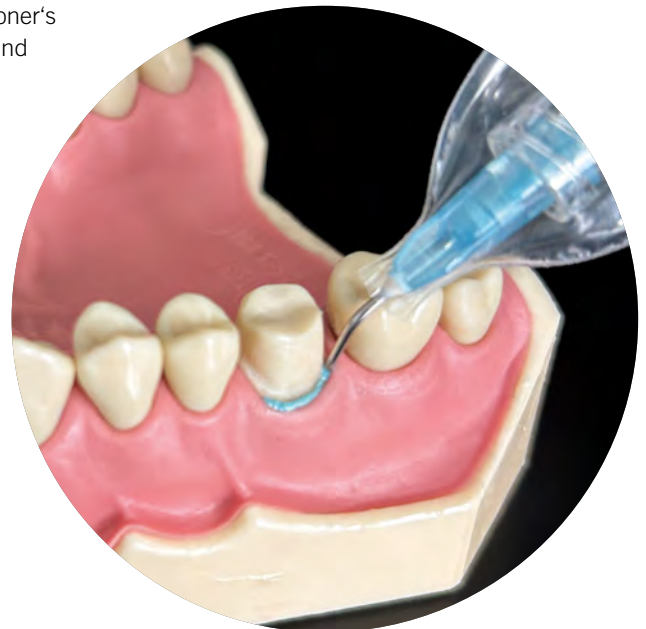Impregnated cords or liquids for impregnating cords can cause a possible adrenaline overdose. They are contraindicated in patients with cardiovascular disease and hypersensitivity to adrenaline. The proportion of the drug that passes into the bloodstream depends on various factors. The uptake is higher the longer the duration of the cord, the greater the total length of cord material used and the more exposed the vascular bed (inflammation, traumatised tissue).¹



Hint: Already pre-impregnated cords must not be additionally impregnated with a retraction solution due to possible interactions.

2.4.2 Pastes

The use of cordless techniques in soft tissue management is becoming increasingly important and meets the practitioner's desire for non-invasiveness, ease of use, effectiveness and time saving as well as increased comfort for the patient. In principle, a distinction is made between purely mechanically displacing pastes and those that offer a combination of mechanical and chemical retraction.



RetraXil

RetraXil is an astringent retraction paste for temporary displacement of marginal gingiva and drying of the gingival sulcus. In addition to the displacement effect of the paste, the astringent aluminium chloride (15%) provides a haemostatic effect.



RetraXil retraction paste can be used before both analogue and digital impressions. It can also be used for cementing temporary and permanent restorations as well as for Class II and Class V fillings. The different application possibilities are presented in the following paragraph.



Tip: Depending on the clinical situation and the personal preference of the practitioner, the paste can be used in combination with retraction cords for deep subgingival preparations.

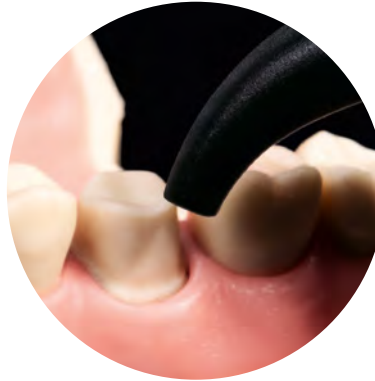
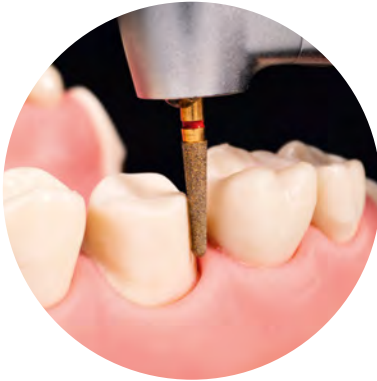
Hint: RetraXil is contraindicated in cases of known or suspected allergy to product ingredients. RetraXil must not be used on diseased periodontium, exposed furcations or exposed bone.

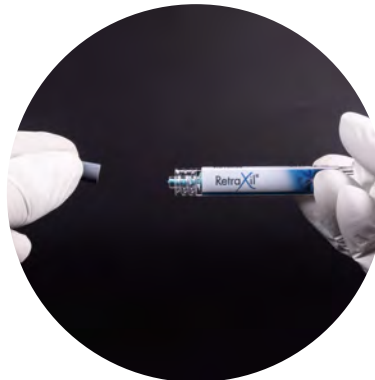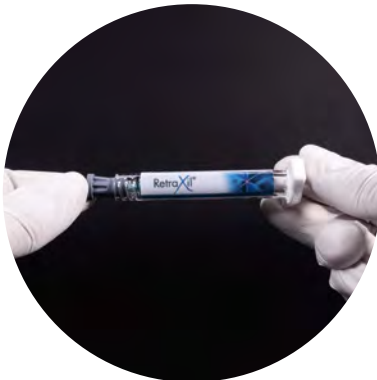3.1 Use of RetraXil in different indications

3.1.1 Analogue impression

1. After the tooth has been prepared, the sulcus is thoroughly rinsed with water and carefully dried with air before using the paste.

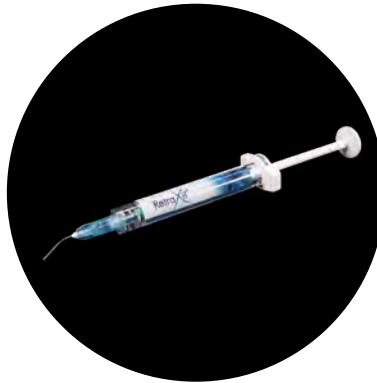
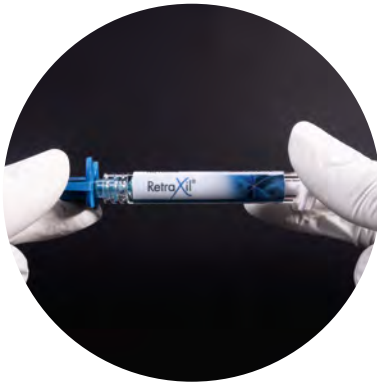
2. The cap is removed from the syringe and stored.

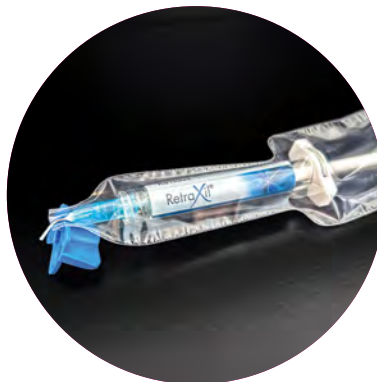
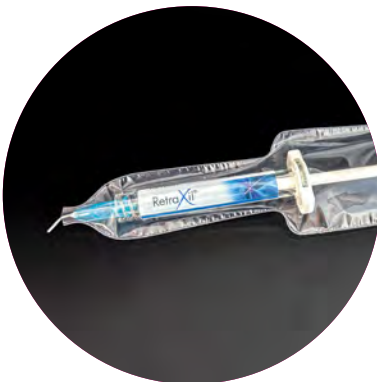
Tip: Keep the cap in a suitable place, it will be needed again at the end of the treatment to close the syringe.

3. The application cannula is screwed on and tightened by means of the twisting aid. A protective sleeve is used to protect the syringe with application cannula against contamination.

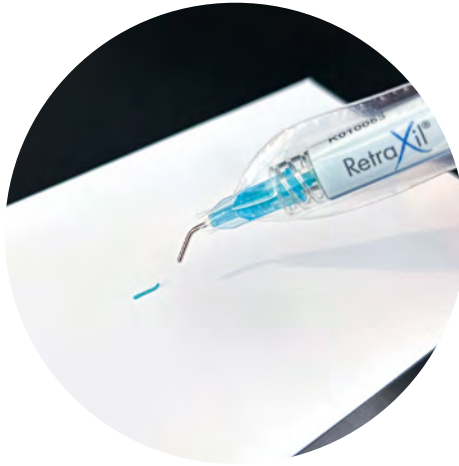

Hint: Twisting aid must be sterilised before first use and cleaned, disinfected and sterilised after each use.



Tip: During treatment, the syringe can be placed on the twisting aid.

4. A small amount of retraction paste is applied to a mixing pad before each use and discarded.

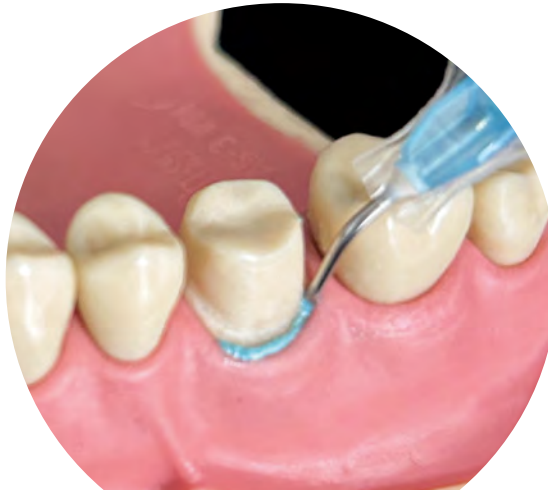

Hint: The pre-bent application cannula must not be bent!

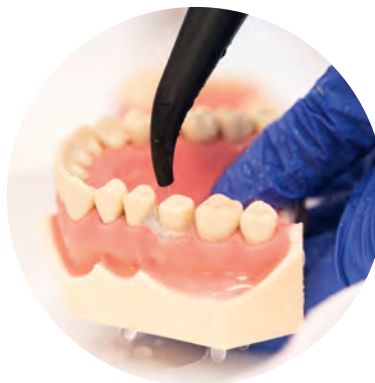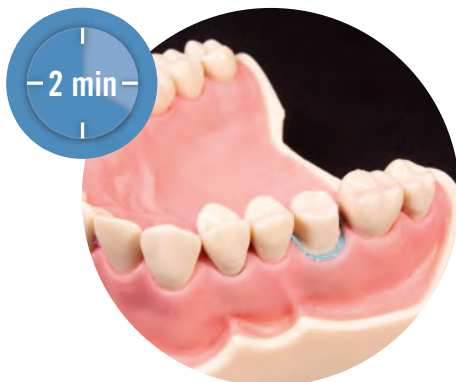5. The application cannula is inserted into the sulcus and the retraction paste is applied circularly around the tooth.



Tip: Sufficient material has been applied if excess material is flowing out of the sulcus.

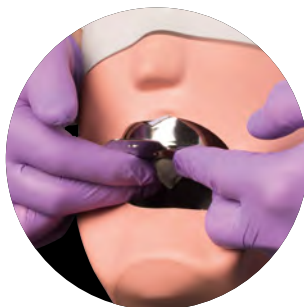
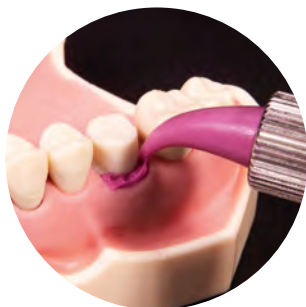
6. The retraction paste is left in the sulcus for two minutes and then removed with a water-air mixture and suction device without leaving any residue and the tooth surface is dried.



Hint: A longer exposure time must be avoided at all costs, as the aluminium chloride content in the paste can lead to tissue damage if exposed for a longer time. Always pay attention to the specified exposure time according to the instructions for use.

The impression is taken directly after the successful retraction procedure.



Cleaning and disinfection process follows on pages 32ff, and must be carried out after each use.

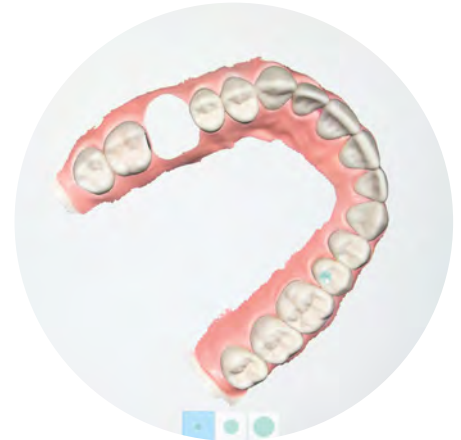
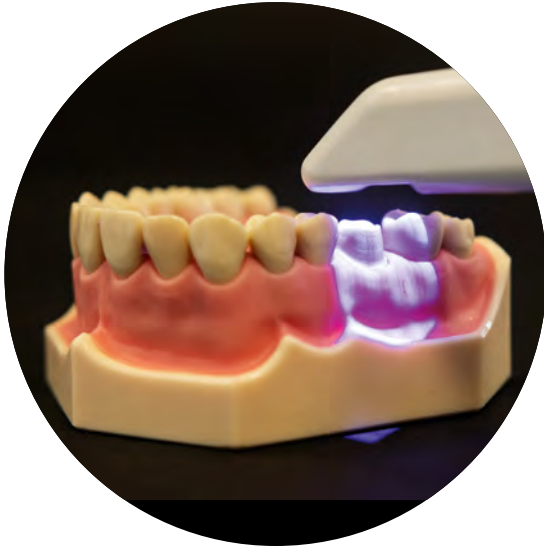
Tip: Make sure to rinse out the paste sufficiently so as not to negatively influence the quality of the impression.


3.1.2 Digital impression

Even with digital impressions, it is essential to temporarily open the sulcus for optimal detection of the preparation margin and to stop bleeding to allow optical detection of the surfaces to be scanned. As with analogue impressions, the tooth is prepared and then the sulcus is rinsed with water and dried with air. A small amount of RetraXil paste is discarded on the mixing pad. RetraXil is then introduced into the sulcus and applied circularly, also during the subsequent digital impression. The paste is left in the sulcus for two minutes and then removed with a water-air mixture and a suction device and the tooth surface is dried with air. The scanning process is started followed by cleaning and disinfection of twisting aid and finger support.





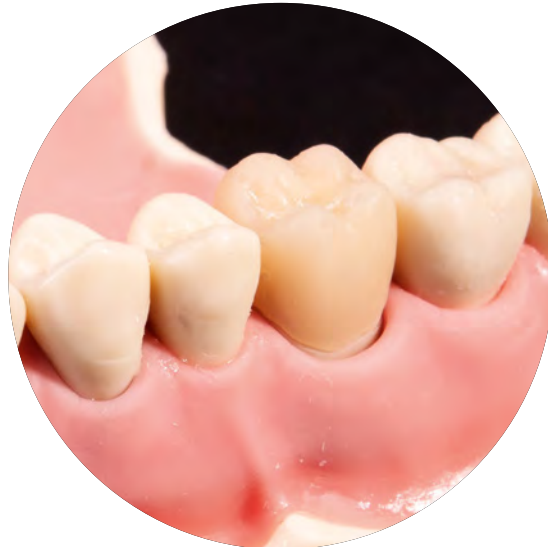Tip: The jaw to be treated and the opposing jaw can already be scanned before the preparation. The area of the teeth to be prepared is cut out with the software and after preparation and retraction these partial areas are rescanned.



3.1.3 Before cementing temporary and definitive restorations

Temporary crowns and bridges are usually cemented with zinc oxide eugenol cements or eugenol-free cements. Definitive restorations are placed with conventional cements (e.g. phosphate cement), adhesive composite cements or self-adhesive composite cements. While relative isolation of the tooth surfaces is usually sufficient with conventional cements, absolute isolation is essential with adhesive and self-adhesive systems.

As with retraction before analogue or digital impressions, steps 1–6 are carried out first. The prosthetic restoration is then fitted.



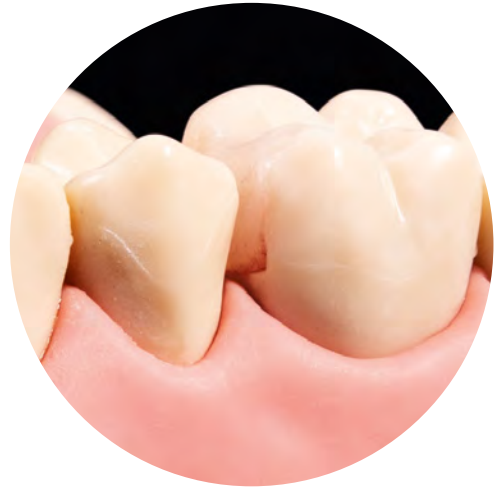

Tip: If relative isolation is sufficient due to the existing conditions and the selected cement, the temporary or definitive restoration is placed after successful try-in and occlusion check and excess cement is removed. If the working area has to be absolutely isolated, this is done by placing a rubber dam after applying the paste.

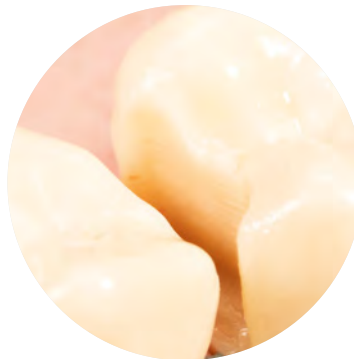3.1.4 Before placing Class V/II fillings

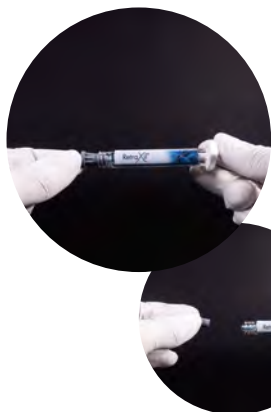Equi,- or subgingival filling margins are a challenge in dental practice in several respects. On the one hand, adhesive luting systems require the cavity to be restored to be absolutely dry in order to ensure an optimum bond and marginal seal. Secondly, for aesthetic reasons, discolouration of the composite with blood and staining residues must be avoided.

After the tooth has been prepared, the sulcus is thoroughly rinsed with water and carefully dried with air before using the paste.

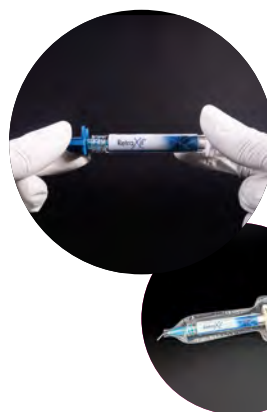

Due to insufficient haemostasis and cleaning of the cavity, the filling margin shows severe discolouration.

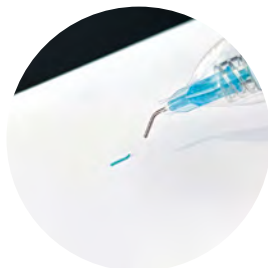



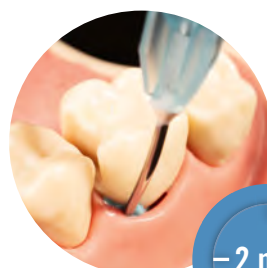1. The cap is removed from the syringe and stored.



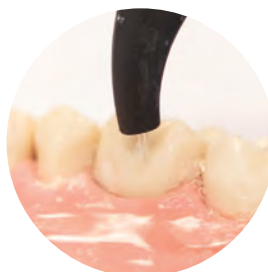2. The application cannula is twisted on and tightened by means of the twisting aid. A protective sleeve is used to protect the syringe with application cannula against contamination.



3. A small amount of retraction paste is applied to a mixing pad before each use and discarded.



4. The application cannula is inserted into the sulcus and the retraction paste is applied circularly around the tooth.



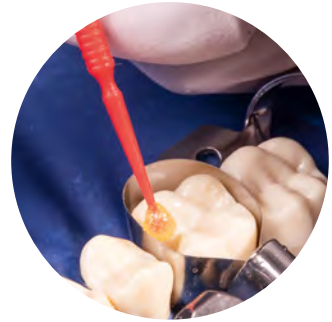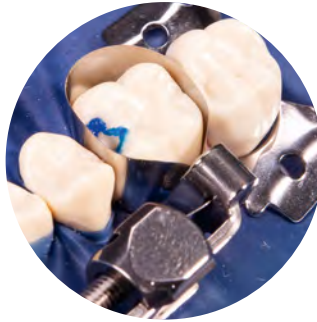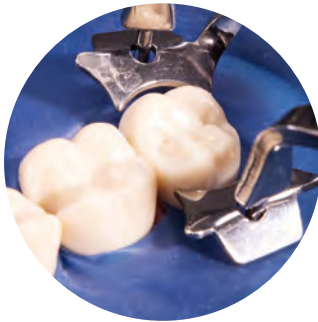5. The retraction paste is left in the sulcus for two minutes and then removed from the sulcus with a water-air mixture and suction device without leaving any residue and the tooth surface is dried.



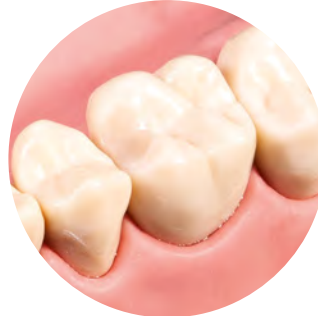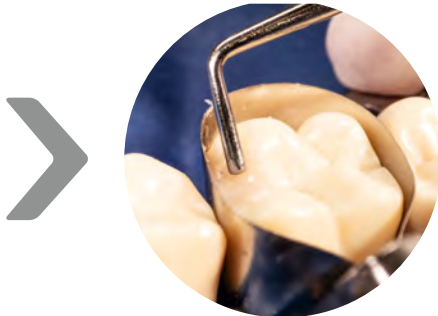Hint: Make sure that RetraXil does not get on the prepared tooth surface. The product may affect the bonding of dentin adhesives.



Tip: If it is possible to apply a rubber dam, the aim should be to achieve absolute isolation.



If necessary, the cavity is conditioned with phosphoric acid, rinsed and then a bonding agent is used according to the manufacturer's instructions.

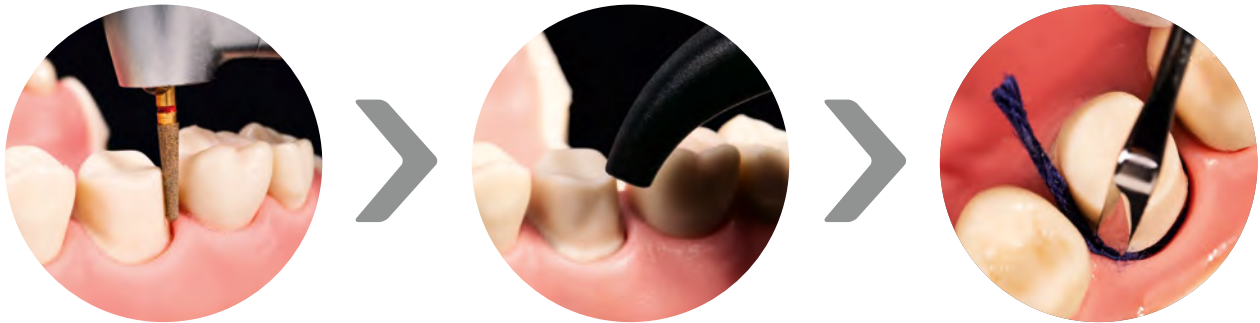

The cavity is then filled with the corresponding filling material, which is then light-cured.

After polymerisation, the rubber dam is removed and the filling is finished and polished.

3.1.5 In combination with retraction cords (e.g. for deep subgingival preparations)

Deep subgingival preparation margins may require the placement of a cord in combination with the use of RetraXil, depending on the clinical situation and practitioner preference.

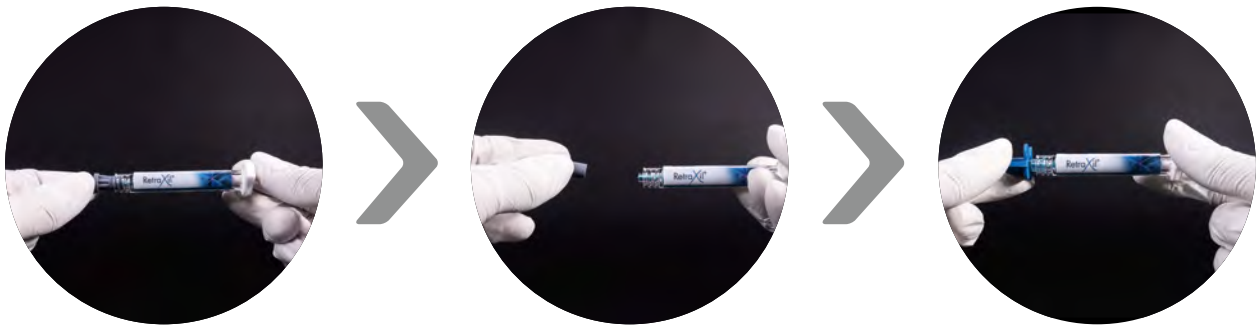

1. & 2. After the tooth has been prepared, the sulcus is thoroughly rinsed with water and carefully dried with air before the paste is used.

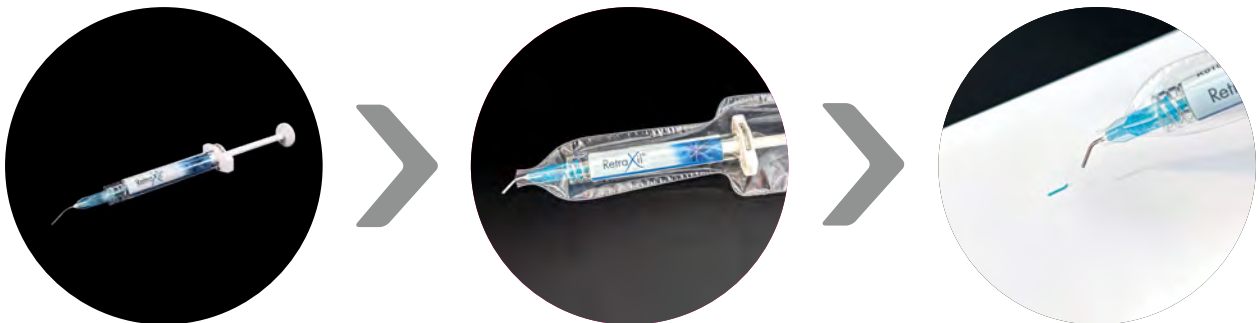3. A cord chosen according to the clinical situation is inserted into the sulcus with a retraction cord packing instrument.



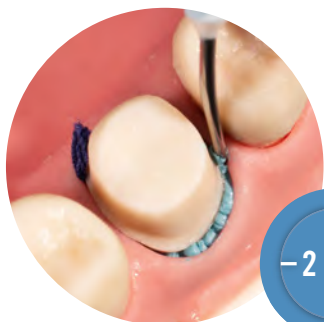
Hint: Medicinal additives must not be mixed with each other or introduced into the sulcus at the same time. Interactions cannot be excluded!



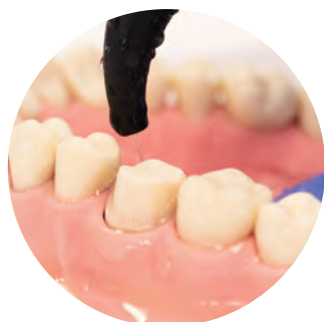4.–6. Remove the cap from the syringe and keep it in place. The application cannula is twisted on and tightened by means of the twisting aid.



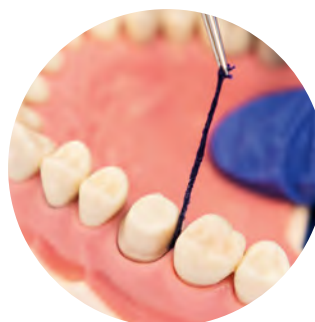7.–9. A protective sleeve is used to protect the syringe with application cannula against contamination. A small amount of retraction paste is applied to a mixing pad before each use and discarded.



- 10.** The application cannula is inserted into the sulcus and the retraction paste is applied circularly around the tooth.



- 11.** The retraction paste is left in the sulcus for two minutes and then removed with a water-air mixture and suction device without leaving any residue.



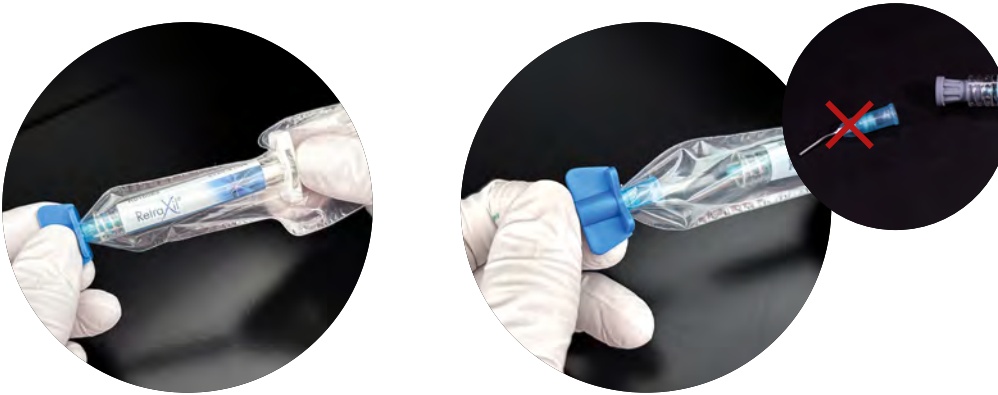- 12.** The cord is then removed from the sulcus and the tooth surface is cleaned and dried. This is followed by cleaning and disinfection of twisting aid and finger support.



Tip: To allow additional expansion of the sulcus, the cord can also be left in the sulcus during impression taking if it does not touch the preparation margin. It is important to remove it after the impression has been taken.

04

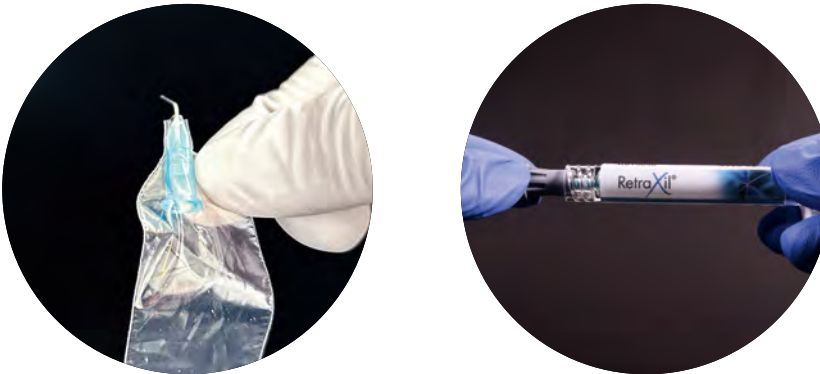
Cleaning and disinfection



After applying the paste, the application cannula together with the protective sleeve is twisted off using the twisting aid.



Hint: The application cannula and the protective sleeve are intended for single use. Both must be discarded after use.



The grey cap is put back on.



Hint: Only validated processes may be used for reprocessing medical devices!



Tip: Reprocess the twisting aid as soon as possible, at most within two hours after use.


4.1 Cleaning and disinfection of the twisting aid

4.1.1 Cleaning and disinfection by hand

A suitable cleaning solution (e.g. ID212, Dürr Dental) is prepared according to the manufacturer's instructions and the twisting aid must be completely immersed.



Hint: Hard-to-reach areas must be cleaned with a soft brush.

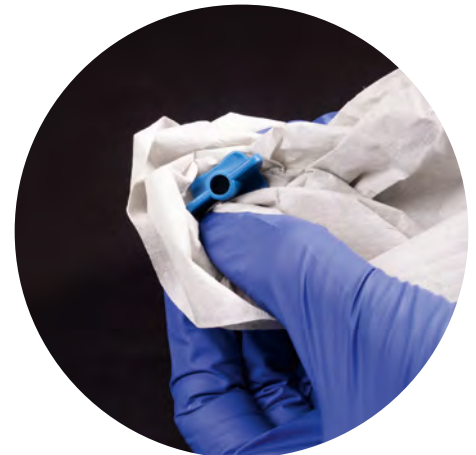

The twisting aid must remain in the cleaning solution according to the exposure time specified by the manufacturer.



The twisting aid is then removed and rinsed thoroughly under running water (30 seconds).

Now prepare the disinfectant according to the manufacturer's instructions (e.g. ID 212, 2 %). Immerse the twisting aid completely in the disinfectant and remove it after the specified exposure time (e.g. 5 min.). Rinse it thoroughly (e.g. 30sec.) with demineralised water. After rinsing, the twisting aid is dried with a lint-free disposable cloth or medical compressed air.



Hint: If there is still visible soiling, the cleaning must be repeated.

4.1.2 Cleaning and disinfection: Automated disinfection

To prepare, clean the twisting aid for one minute under running water with a soft brush (e.g. Interlock).



The pre-cleaned twisting aid is placed in a suitable sieve tray and disinfected accordingly in a washer-disinfector according to DIN EN ISO 15883-1 and 2 with a thermal programme and the addition of a mildly alkaline cleaner (e.g. Neodisher Mediclean forte, Dr. Weigert).

The twisting aid is removed at the end of the programme and dried with a lint-free cloth or medical compressed air.

Hint: If there is dirt left, it must be cleaned manually and the process must be repeated.

05

Sterilisation


The twisting aid is wrapped in a suitable sterile barrier system and placed in the sterilisation chamber of a steriliser according to DIN EN 285 or small steam steriliser according to DIN EN 13060, type B. Steam sterilisation is carried out at 134 °C and a holding time of at least 3 minutes or 132 °C for at least 4 minutes or longer.



Tip: In Germany, a holding time of at least 5 minutes is recommended based on the KRINKO/BfArM recommendation.




Tip: When using foil-paper packaging for the sterile barrier system, ensure that the packaging is of sufficient size to guarantee tension-free packaging and an intact seal.



Start the sterilisation programme and remove the medical devices at the end of the programme.




Hint: All medical devices must always be checked for damage and wear and must be sorted out and discarded if necessary.



After cooling down, check the packages for damage



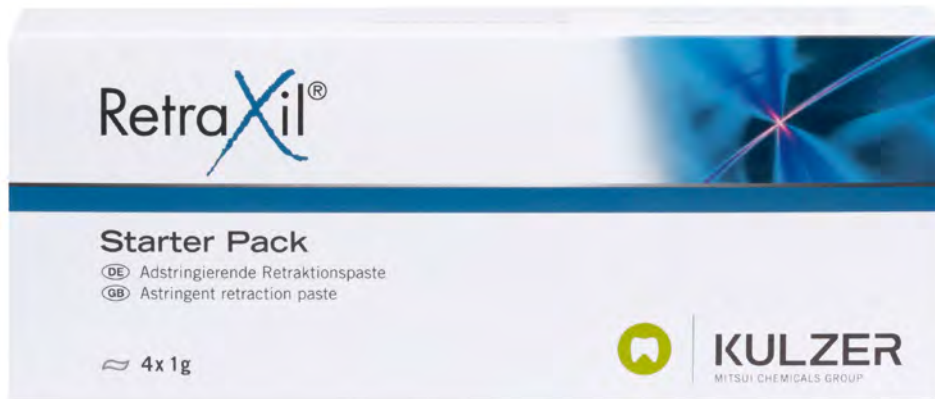
Hint: Damaged packages are non-sterile and must be repackaged and sterilised.



Sources

- 1 Wald, A. Rehmann, P. Wöstmann, B. Weichgewebsmanagement bei der Abformung präparierter Zähne. ZMK (27). 6/2011. S.392-397
- 2 Glantz, P.O. Nyman, S. Technical and biophysical aspects of fixed partial dentures for patients with reduced periodontal support. J Prosthet Dent 47. 1982. 47-51
- 3 Laufer BZ, Baharav H, Langer Y, Cardash HS. The closure of the gingival crevice following gingival retraction for impression making. J Oral Rehabil. 1997 Sep;24(9):629-35
- 4 Agarwal, Bhaskar & Balendra, & Singh, balendra pratap & Sing, Nishi & Chand, Pooran & Srivastava, Shitij. (2015). INDIAN DENTAL JOURNAL EFFECT OF GINGIVAL DISPLACEMENT CORD ON THE CLOSURE RATE OF GINGIVAL CREVICE: META-ANALYSIS. Indian Dental Journal 2320-2769. 7. 3-8.
- 5 Baharav H, Kupersmidt I, Laufer BZ, Cardash HS. The effect of sulcular width on the linear accuracy of impression materials in the presence of an undercut. Int J Prosthodont. 2004 Sep-Oct;17(5):585-9. PMID: 15543916
- 6 Woestmann, B. Abformung auf neuen und alten Wegen. ZM (10).2016. 40-47
- 7 Biscopig, S. Woestmann, B. Wichtige Tips für die korrekte Abformung. Qdent. 2017. 1(1).12-16
- 8 Wöstmann B. Klinische Bestimmungsvariablen bei der Abformung präparierter Zähne. Z Stomatol 1996;93:51–57
- 9 Strub, J. Türp, J. Witkowski, S. Hürzeler, M. Kern, M. Klinik: Postpräparatorische Maßnahmen am Patienten. In: Curriculum Prothetik. Quintessenz Verlags GmbH. 2003. S.777
- 10 Marxkors, R. Lehrbuch der zahnärztlichen Prothetik. Deutscher Zahnärzte Verlag. 2007.S.46
- 11 Horn, F. Lindenmeier, G. Moc, I. Grillhösl, C. Berghold, S. Schneider, N. Münster, B. Blutstillung. In: Biochemie des Menschen. Georg Thieme Verlag. 2002. S.501 ff.
- 12 Pelzner RB, Kempler D, Stark MM, Lum LB, Nicholson RJ, Soelberg KB. Human blood pressure and pulse rate response to racemic epinephrine retraction cord. J Prosthet Dent. 1978 Mar;39(3):287-92
- 13 Woestmann, B. Rosentritt, M. Ilie, N. Lohbauer, U. Abformmaterialien. In: Werkstoffkunde der Zahnmedizin.Georg Thieme Verlag KG. 2018. S.23-54

- 14 Herold,G. Hämatologie. In: Innere Medizin. 2013. S.129 ff.
- 15 Schwenzer, N. Ehrenfeld, M. Blutung und Blutstillung. In: Allgemeine Chirurgie. Georg Thieme Verlag. 2000. S. 27 ff.
- 16 Akca EA, Yildirim E, Dalkiz M, Yavuzylmaz H, Beydemir B. Effects of different retraction medicaments on gingival tissue. Quintessence Int. 2006 Jan;37(1):53-9
- 17 Tosches, N. Salvi, G. Methoden der gingivalen Retraktion. Schweiz Monatsschr Zahnmed. Vol. 119. 2009. S.121 ff.
- 18 Donovan T. E., Chee W. W.: Current concepts in gingival displacement. Dent Clin. North Am 48:433-444 (2004).
- 19 Ahmed SN, Donovan TE. Gingival displacement: Survey results of dentists' practice procedures. The Journal of Prosthetic Dentistry. 2015 Jul;114(1):81-5
- 20 Ruel J, Schuessler PJ, Malament K, Mori D. Effect of retraction procedures on the periodontium in humans. J Prosthet Dent. 1980 Nov;44(5):508-15



Contact in Germany

Kulzer GmbH
Leipziger Straße 2
63450 Hanau
Germany
info.dent@kulzer-dental.com

kulzer.com